

Impact of native iliac vein aspect ratio on initial clinical presentation and outcomes following stenting for symptomatic chronic iliofemoral venous obstruction

Hayden Butts, BS, and Arjun Jayaraj, MD, Jackson, MS

ABSTRACT

Objective: Venous stenting has become the first line of treatment for patients with symptomatic chronic iliofemoral venous obstruction (CIVO) in whom conservative therapy has failed. Intravascular ultrasound (IVUS) interrogation with the use of normal minimal luminal diameters or areas has become the standard to confirm the diagnosis and determine the adequacy of stenting. However, the aspect ratio (ratio between the maximal and minimal luminal diameters) has also been put forth as a possible metric for determining stent adequacy. This study explores the utility of the native iliac vein and stent aspect ratios in determining the initial presentation and outcomes after stenting.

Methods: A retrospective analysis of contemporaneously entered data from patients who underwent stenting for quality of life (QoL)-impairing clinical manifestations of CIVO for whom conservative therapy had failed formed the study cohort. The limbs were grouped into three at the time of intervention using the IVUS-determined native vein aspect ratio: group I, those with a ratio of ≤ 1.4 ; group II, those with a ratio of 1.41 to 1.99; and group III, those with a ratio of ≥ 2 . The characteristics appraised initially and after stenting included the venous clinical severity score, grade of swelling (GOS), visual analog scale (VAS) for pain score, and the CIVIQ-20 QoL score. Analysis of variance and paired and unpaired *t* tests were used for comparison of clinical and QoL variables, and Kaplan-Meier analysis was used to evaluate stent patency, with the log-rank test used to discriminate between different curves.

Results: There were a total of 236 limbs (236 patients). The median age for the entire cohort was 62 years (range, 16-92 years). There were 161 women in the study, and left laterality was more common (137 limbs). Post-thrombotic obstruction was noted in 201 limbs (86%). The median body mass index was 36 kg/m². There were 54 (23%), 64 (27%), and 118 (50%) limbs in groups I, II, and III, respectively. The median follow-up was 65 months. For the entire cohort, after stenting, the venous clinical severity score improved from 6 to 4 ($P < .0001$) at 3 months and remained at 4 at 6 months ($P < .0001$), 12 months ($P < .0001$), and 24 months ($P < .0001$). The GOS for the entire cohort improved from 3 to 1 ($P < .0001$) at 3 months and remained at 1 at 6 months ($P < .0001$), 12 months ($P < .0001$), and 24 months ($P < .0001$). The VAS for pain score for the entire cohort improved from 7 to 0 ($P < .0001$) at 3 months, increased to 2 ($P < .0001$) at 6 months, and remained at 2 ($P < .0001$) at 12 months. At 24 months, the VAS for pain score worsened to 3 ($P < .0001$). For the entire cohort, the CIVIQ-20 score improved from 62 to 40 ($P < .0001$). There was no difference in the GOS, VAS for pain score, or CIVIQ-20 score between the groups at baseline or at 6, 12, and 24 months after intervention. At 60 months, the primary stent patency was 89% for group I, 80% for group II, and 75% for group III ($P = .85$). The primary assisted stent patency was 100% for group I, 98% for group II, and 98% for group III ($P = .5$). Secondary patency was 100% for groups II and III ($P > .5$). Reintervention was pursued for QoL-impairing clinical manifestations in 53 limbs (22%) without a significant difference between the three groups ($P = .13$).

Conclusions: The native vein aspect ratio does not appear to determine the initial clinical presentation or QoL or impact the clinical or QoL outcomes after stenting for CIVO. Following stenting, no patient had an aspect ratio > 2 , with 97% of patients having an aspect ratio ≤ 1.4 and the remaining 3% having an aspect ratio of 1.41 to 1.99. IVUS-determined minimal cross-sectional luminal area and not the aspect ratios should be used for confirmation of the diagnosis of CIVO and to assess the adequacy of stenting. (J Vasc Surg Venous Lymphat Disord 2024;12:101900.)

Keywords: Aspect ratio; Iliac vein stenting; Iliofemoral venous obstruction; May Thurner syndrome; Post thrombotic syndrome

From The RANE Center for Venous & Lymphatic Diseases, St. Dominic Hospital.
Correspondence: Arjun Jayaraj, MD, The RANE Center for Venous & Lymphatic Diseases, St. Dominic Hospital, 971 Lakeland Dr, Ste 401, Jackson, MS 39216 (e-mail: jjayaraj.arjun2015@gmail.com).

The editors and reviewers of this article have no relevant financial relationships to disclose per the Journal policy that requires reviewers to decline review of any manuscript for which they may have a conflict of interest.

2213-333X

Copyright © 2024 The Author(s). Published by Elsevier Inc. on behalf of the Society for Vascular Surgery. This is an open access article under the CC BY-NC-ND license (<http://creativecommons.org/licenses/by-nc-nd/4.0/>).

<https://doi.org/10.1016/j.jvs.2024.101900>

The aspect ratio refers to the ratio between the maximum and minimum diameters of a lumen. For a circle, the aspect ratio would be 1, and for an elliptical lumen, the aspect ratio would be >1 . Recently, data have been put forth through a subanalysis of the VIRTUS trial (VIRTUS safety and efficacy of the Veniti Vici Venous Stent System [Veniti, Inc] when used to treat clinically significant chronic non-malignant obstruction of the iliofemoral venous segment) cohort of 30 patients. The Pearson correlation coefficient was computed between the post-stent cross-sectional area (CSA) change and 12-month venous clinical severity score (VCSS) after stenting and the post-stent aspect ratio change and 12-month VCSS.¹ It was noted that there was no relationship between the postprocedure CSA and VCSS improvement ($r = -0.25$; $P = .211$), although a moderately positive correlation was noted between a lower aspect ratio and clinical improvement after stenting ($r = -0.5$; $P = .008$).¹ This brings forth an important issue, because the CSA is often used to confirm the diagnosis and adequacy of stenting. Luminal areas of 125 mm², 150 mm², and 200 mm² are used as the normal minimal luminal areas in the common femoral vein, external iliac vein, and common iliac vein, respectively.² Any luminal areas less than these cutoffs in a patient with quality of life (QoL)-impairing symptoms despite optimal conservative therapy warrants stenting.^{3,4} Post-stent adequacy is assessed based on the attainment of appropriate luminal areas.³⁻⁷ Attainment of an aspect ratio of 1 is typically not evaluated, although an aspect ratio close to 1 is expected after stenting. Lichtenberg¹ had noted that to maintain the same flow rate, an increase in pressure would be required to overcome resistance in flow due to a flatter shape (higher aspect ratio). In the healthy native vein, we know from the work of Moreno et al⁸ and Griffiths⁹ that a change occurs in the perimeter of the vein wall, with distention such that the luminal area can increase. However, this might not be the case in the diseased vein where the wall has lost its compliance. Additionally, such a change in perimeter cannot be expected in a stented vein. A recent experimental model demonstrated that a decrease in the aspect ratio of a Penrose drain used to simulate the iliac vein was among several factors that contributed to peripheral venous hypertension.¹⁰ In this background, it is difficult to discern how much impact an aspect ratio >1 can have, especially from a clinical standpoint. In this study, we sought to evaluate the impact of native vein aspect ratios of ≤ 1.4 , 1.41 to 1.99, and ≥ 2 compared with the CSA of the vein lumen on clinical, QoL, and stent-related outcomes and potentially shed more light on the topic.

METHODS

Study design. We performed a single-center, retrospective analysis of data collected from 2013 to 2022. The Franciscan Missionaries of Our Lady University

ARTICLE HIGHLIGHTS

- **Type of Research:** A single-center, retrospective analysis
- **Key Findings:** The native iliac vein aspect ratio does not determine initial clinical presentation or quality of life (QoL) or impact clinical or QoL outcomes after stenting in patients undergoing stenting with the use of intravascular ultrasound-determined minimal cross-sectional luminal areas for QoL-impairing symptoms of chronic iliofemoral venous obstruction after conservative therapy has failed. After stenting, a reduction in the aspect ratio (≤ 1.4 in 97% of limbs and 1.41-1.99 in the remainder) and improvement in clinical and QoL metrics were noted in all stented limbs.
- **Take Home Message:** The intravascular ultrasound-determined minimal cross-sectional luminal area of the iliac segment and not the aspect ratio should serve as the determinant for confirmation of the diagnosis of chronic iliofemoral venous obstruction and assessing the adequacy of stenting. Good outcomes can be expected with this approach.

institutional board review approved the study and dissemination of de-identified patient data. The patients provided written informed consent for all tests and procedures.

Setting. The RANE Center is a tertiary center for the management of venous and lymphatic disorders.

Participants. Patients with QoL-impairing manifestations of chronic iliofemoral venous obstruction (CIVO) in whom conservative therapy has failed and who underwent stenting after intravascular ultrasound (IVUS) confirmation of the diagnosis were included in the study. These symptoms and signs included swelling, heaviness, tiredness, pain, venous claudication, hyperpigmentation, lipodermatosclerosis, and/or venous leg ulcers. Conservative therapy included the regular use of compression stockings, leg elevation as feasible, exercise as tolerated, antithrombotic therapy when appropriate, and complex decongestive therapy for patients with phlebolymphe-dema. Those who underwent stenting for chronic total occlusive lesions, stenting in the setting of acute or subacute iliofemoral venous thrombosis, and those who underwent bilateral stenting were excluded. The study patients were divided on the basis of their native vein aspect ratio into three groups: group I, those with a native vein aspect ratio of ≤ 1.4 ; group II, those with a ratio of 1.41 to 1.99; and group III, those with a ratio of ≥ 2 .

Stenting and follow-up. Confirmation of the diagnosis, technique of stenting, antithrombotic therapy, and follow-up have been described in prior reports.^{3,4,7} In

Table I. Demographic characteristics and CEAP clinical class stratified by aspect ratio group (n = 236)

Variable	Aspect ratio			P value
	≥2 (n = 118; 50%)	1.41-1.99 (n = 64; 27%)	≤1.4 (n = 54; 23%)	
Demographic characteristics				
Age, years	60 (18-92)	64 (16-85)	62 (34-86)	.29
Sex				.06
Male	29	24	22	
Female	89	40	32	
Laterality				< .0001
Left	79	44	14	
Right	39	20	40	
NIVL	21	8	5	.30
PTS	97	55	49	.30
Median BMI, kg/m ²	35.9	35.9	37.8	.42
CEAP clinical class				
C0-C2	1 (1)	1 (2)	2 (4)	.40
C3	21 (18)	14 (22)	9 (17)	.73
C4	79 (67)	36 (56)	31 (57)	.27
C5	6 (5)	5 (8)	5 (9)	.56
C6	11 (9)	8 (13)	7 (13)	.71

BMI, Body mass index; CEAP, clinical, etiologic, anatomic, pathophysiologic; NIVL, nonthrombotic iliac vein lesion; PTS, post-thrombotic syndrome. Data presented as median (range), number, or number (%), unless noted otherwise.

brief, with the patient under general anesthesia, access was obtained in the ipsilateral femoral or popliteal vein (as dictated by the best possible inflow on preoperative imaging). A venogram was initially performed to evaluate the flow characteristics as long as no contraindications existed, followed by IVUS interrogation. If contraindications existed to the use of contrast, only an IVUS evaluation was pursued. Normal minimal luminal areas were used to confirm the diagnosis of CIVO (ie, 125 mm², 150 mm², and 200 mm² in the common femoral, external iliac, and common iliac veins, respectively).² A luminal area less than these cutoffs was used to confirm diagnosis of CIVO, and predilation, stenting, and post-dilation were pursued. Stent sizing was based on the inflow channel luminal area, and stenting was performed from an area of good inflow to an area of good outflow.⁷

Finally, completion IVUS interrogation was performed to ensure adequacy of stenting (attainment of normal minimal luminal areas and good vein wall to stent and stent to stent apposition). Also, a venogram was performed to ascertain the final flow dynamics. Regarding antithrombotic therapy, anticoagulation was continued for patients already receiving it before the procedure. Anticoagulation therapy was started for those with a history of unprovoked venous thromboembolic event, patients with thrombophilia, patients receiving hormonal therapy, intraoperative findings (eg, severe PTS) indicating the need for anticoagulation, and patients with early severe in-stent restenosis on postprocedure duplex ultrasound (DUS). A direct oral anticoagulant was typically used when anticoagulation was started after stenting. Aspirin 81 mg daily was started and continued

Table II. Venous clinical severity score (VCSS) stratified by aspect ratio group at baseline and 3, 6, 12, and 24 months after stenting

VCSS	Aspect ratio			P value
	≥2 (n = 118; 50%)	1.41-1.99 (n = 64; 27%)	≤1.4 (n = 54; 23%)	
Baseline	6 (n = 118)	6 (n = 64)	7 (n = 53)	.001
3 Months	4 (n = 102)	4 (n = 55)	5 (n = 38)	.04
6 Months	4 (n = 84)	4 (n = 47)	4 (n = 34)	.18
12 Months	3 (n = 86)	4 (n = 44)	4 (n = 35)	.10
24 Months	4 (n = 80)	4 (n = 41)	3 (n = 16)	.52

Data presented as median scores with number of limbs in parentheses.

Table III. Grade of swelling (GOS) stratified by aspect ratio group at baseline and 3, 6, 12, and 24 months after stenting

GOS	Aspect ratio			P value
	≥2 (n = 118; 50%)	1.41-1.99 (n = 64; 27%)	≤1.4 (n = 54; 23%)	
Baseline	3 (n = 118)	3 (n = 64)	3 (n = 53)	.07
3 Months	1 (n = 102)	1 (n = 55)	3 (n = 38)	.01
6 Months	1 (n = 84)	1 (n = 47)	1 (n = 34)	.18
12 Months	1 (n = 86)	1 (n = 44)	1 (n = 35)	.41
24 Months	1 (n = 80)	1 (n = 41)	1 (n = 16)	.84

Data presented as median scores with number of limbs in parentheses.

lifelong as long as no contraindications existed. Follow-up was in the form of DUS done before same-day discharge after intervention, with additional DUS examinations and clinic visits at 3 weeks, 3 months, 6 months, and 12 months after intervention and yearly thereafter. Closer follow-up was pursued if there was concern for clinical recurrence and/or stent malfunction. The technique of stenting, peri- and postoperative care, and follow-up have been described previously.^{3,5,11}

Reintervention. Reintervention was pursued for patients who developed recurrence of QoL-impairing clinical manifestations. These limbs underwent repeat IVUS interrogation and consequent correction of the etiology of their stent malfunction. This malfunction varied from in-stent restenosis to stent compression to a combination of the two to stent occlusion. The technique for the diagnosis of stent malfunction and its correction have also been described in prior reports.¹²⁻¹⁴

Outcomes assessed. The clinical metrics evaluated included the VCSS (range, 0-27 [3-30 for compression stockings]), visual analog scale (VAS) for pain score (range, 0-10), and grade of swelling (GOS; range, 0-4). The GOS was categorized as 0, no swelling; 1, pitting, nonobvious swelling; 2, visible ankle swelling; 3, gross swelling involving the leg up to the knee; and 4, gross swelling involving the entire leg, including the thigh. All scores were appraised at baseline and at every clinic follow-up visit after stenting. QoL was assessed using the CIVIQ-20 questionnaire, which has a maximum score of

100 (indicating the worst possible QoL) and a score of 0 (indicating the best possible QoL).^{15,16} The last follow-up response available for the CIVIQ-20 questionnaire was used in the postoperative outcome analysis.

Statistical analysis. Statistical analysis was performed using Prism, version 8 (GraphPad). Comparisons were made using analysis of variance, χ^2 test, and unpaired and paired *t* tests. The limb counts used for analysis are noted in the results as appropriate. Kaplan-Meier analysis was used to assess stent patency after intervention, with the log-rank test used to discriminate between curves. *P* ≤ .05 was considered significant.

RESULTS

There was a total of 236 limbs (236 patients). The median age for the entire cohort was 62 years (range, 16-92 years). There were 161 women in the study, and left laterality was more common (137 limbs). Post-thrombotic obstruction was noted in 201 limbs and nonthrombotic iliac vein lesions (NIVLs) in the remainder. The median body mass index was 36 kg/m². Regarding the CEAP (clinical, etiologic, anatomic, pathophysiologic) clinical class, there were 4 limbs (2%) in the C0-C2 class, 44 limbs (19%) in the C3 class, 146 limbs (62%) in the C4 class, 16 limbs (7%) in the C5 class, and 26 (11%) in the C6 class. The C0-C2 limbs underwent intervention due to QoL-impairing venous claudication that persisted despite optimal conservative therapy. The demographic data for the individual groups are presented in Table I. The median follow-up was 65 months (range 1-119 months).

Table IV. Visual analog scale (VAS) for pain scores stratified by aspect ratio group at baseline and 3, 6, 12, and 24 months after stenting

VAS for pain score	Aspect ratio			P value
	≥2 (n = 118; 50%)	1.41-1.99 (n = 64; 27%)	≤1.4 (n = 54; 23%)	
Baseline	6 (n = 117)	8 (n = 62)	8 (n = 49)	0.22
3 Months	0 (n = 100)	0 (n = 53)	4 (n = 36)	0.07
6 Months	0 (n = 79)	1 (n = 44)	4 (n = 31)	0.54
12 Months	0 (n = 84)	4 (n = 42)	4 (n = 34)	0.54
24 Months	3 (n = 75)	5 (n = 40)	3 (n = 12)	0.89

Data presented as median scores with number of limbs in parentheses.

Table V. Quality of life: CIVIQ-20 questionnaire scores stratified by aspect ratio group at baseline and after stenting

CIVIQ-20 score	Aspect ratio			P value
	≥2 (n = 118; 50%)	1.41-1.99 (n = 64; 27%)	≤1.4 (n = 54; 23%)	
Baseline	66 (n = 39)	54 (n = 22)	61 (n = 28)	.45
After stenting	42 (n = 39)	45 (n = 22)	38 (n = 28)	.73

Data presented as median scores with number of limbs in parentheses.

Clinical outcomes

Venous clinical severity score. Overall, for the entire cohort, the VCSS improved from 6 to 4 ($P < .0001$) at 3 months and remained at 4 at 6 months ($P < .0001$), 12 months ($P < .0001$), and 24 months ($P < .0001$). The VCSS improvements in the three subgroups at 3, 6, 12, and 24 months are presented in Table II.

Grade of swelling. The GOS for the entire cohort improved from 3 to 1 ($P < .0001$) at 3 months and remained at 1 at 6 months ($P < .0001$), 12 months ($P < .0001$), and 24 months ($P < .0001$). The GOS improvements in the three subgroups at 3, 6, 12, and 24 months are presented in Table III.

VAS for pain score. The VAS for pain score for the entire cohort improved from 7 to 0 ($P < .0001$) at 3 months, increased to 2 ($P < .0001$) at 6 months, and remained at 2 ($P < .0001$) at 12 months. At 24 months, the VAS for pain score worsened to 3 ($P < .0001$). The VAS for pain score improvements in the three subgroups at 3, 6, 12 and 24 months are presented in Table IV.

Ulcer healing. Of the 26 limbs with ulcers, 21 (81%) healed during the duration of follow-up. The median time to healing was 4 months. Of the unhealed ulcers, two were in group II and three in group I. A recurrence rate of 38% (8 of 21) was noted. Of the ulcers that

recurred, six were in group III and two were in group II. There were no recurrences in group I.

Quality of life. For the entire cohort, the CIVIQ-20 score improved from 62 to 40 ($P < .0001$). The improvement for each group is presented in Table V.

Aspect ratio after stenting. For the entire cohort, the median aspect ratio improved from 2 before stenting to 1.14 after stenting ($P < .0001$). Correspondingly, the median minimal luminal area improved from 123 mm² before stenting to 192 mm² after stenting ($P < .0001$). Following stenting, there were no limbs with a stent aspect ratio of ≥2. Seven limbs had an aspect ratio 1.41 to 1.99. The remaining 229 limbs had an aspect ratio of ≤1.4. For group I (aspect ratio of ≤1.4), the median native vein aspect ratio was 1.3, which improved to 1.15 after stenting ($P < .0001$). For group II (aspect ratio, 1.41-1.99), the median native vein aspect ratio was 1.7, which improved to 1.13 after stenting ($P < .0001$). For group III (aspect ratio of ≥2), the median native vein aspect ratio was 2.6, which improved to 1.17 after stenting ($P < .0001$). When analyzed by the nature of the obstruction (post-thrombotic obstruction vs NIVL), at baseline, the median native vein aspect ratio for the NIVL cohort was 2.21 and was 1.98 for the post-thrombotic obstruction cohort, without a significant difference between the two

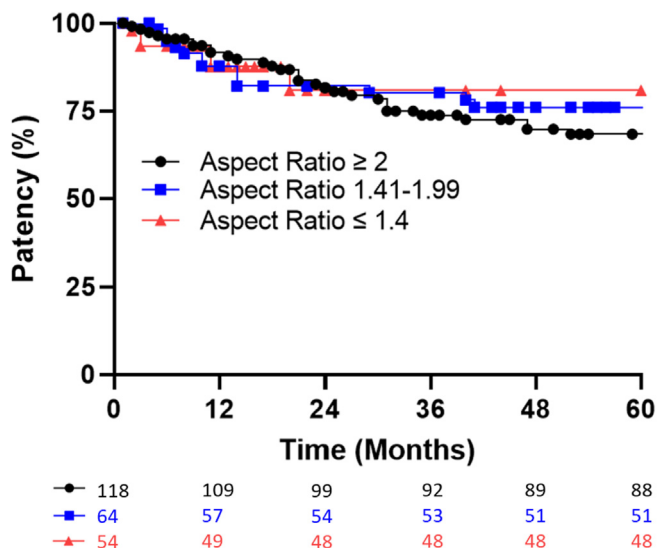


Fig 1. Plot demonstrating primary stent patency for the three groups (standard error of the mean, <10%).

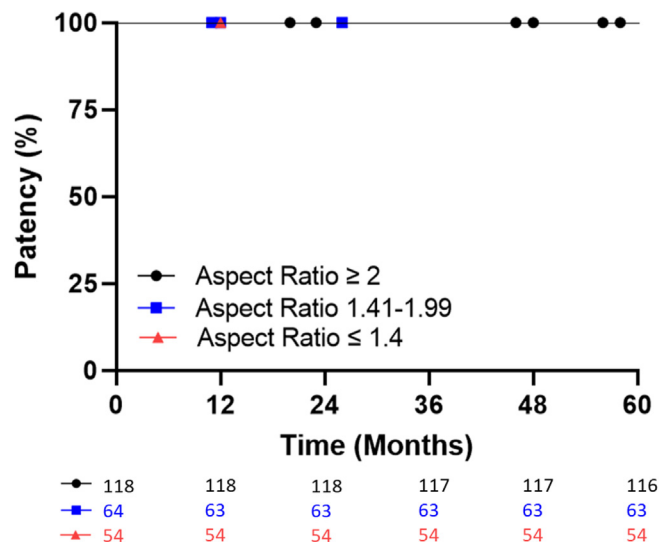


Fig 2. Plot demonstrating primary assisted stent patency for the three groups (standard error of the mean, <10%).

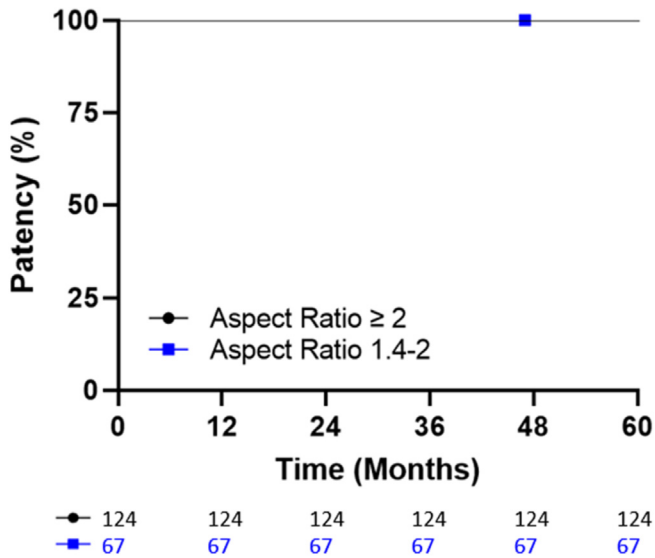


Fig 3. Plot demonstrating secondary stent patency for the three groups (standard error of the mean, <10%).

($P = .06$). After stenting, the aspect ratio improved to 1.13 in the NIVL cohort and 1.14 in the post-thrombotic obstruction cohort, again without a difference between the two groups ($P = .77$). Additionally, after stenting, there was a significant improvement in the clinical (VCSS, GOS, VAS for pain score) and QoL (CIVIQ-20 score) parameters in both the NIVL and the post-thrombotic obstruction groups at the various time points.

Stent outcomes

Stent patency. Overall, for the entire cohort, the primary, primary assisted, and secondary patency at 60 months was 79%, 99%, and 100%, respectively. For group I (aspect ratio, ≤ 1.4), at 60 months, primary patency was 89% and primary assisted patency was 100%. No stent occlusions occurred in group I. For group II (aspect ratio, 1.41-1.99), at 60 months, primary patency was 80%, primary assisted patency was 98%, and secondary patency was 100%. For group III (aspect ratio, ≥ 2), at 60 months, primary patency was 75%, primary assisted patency was 98%, and secondary patency was

100%. The patency curves for each group are presented in Figs 1 to 3.

Reintervention. Reintervention for the entire cohort was required for 53 of 236 limbs (22%). In group I (aspect ratio, ≤ 1.4), reintervention was pursued in six limbs (11%). In group II (aspect ratio, 1.41-1.99), reintervention was required for 15 limbs (23%). In group III (aspect ratio, > 2), reintervention was required for 32 limbs (27%). The differences were not statistically significant between the three groups ($P = .06$). The need for reintervention was dictated by the recurrence of QoL-impairing symptoms. The most common cause of reintervention was a combination of in-stent restenosis and stent compression (27 limbs), followed by in-stent restenosis (21 limbs), stent occlusion (4 limbs), and, finally, isolated stent compression (1 limb). The breakdown of reinterventions across the three groups is presented in Table VI.

DISCUSSION

Stenting has become the first-line treatment for patients with QoL-impairing symptoms of CIVO in whom conservative therapy has failed. Although IVUS had become the standard for confirmation of the diagnosis and to assess the adequacy of stenting, with the minimal luminal diameters or areas serving as the appropriate metric, recently, concerns have been raised regarding whether the aspect ratio would serve as a better metric.¹ In this study, we sought to explore this topic by evaluating the initial presentation and outcomes after stenting across a range of aspect ratios.

Aspect ratio and initial clinical presentation and outcomes. The aspect ratio (ie, < 1.4 , 1.41-1.99, ≥ 2) does not appear to determine the initial clinical presentation. This is demonstrated across the GOS and the VAS for pain score. Although there was a significant difference in the VCSS at baseline, with a VCSS of 6 in those with an aspect ratio of 1.41 to 1.99 and ≥ 2 and a VCSS of 7 in those with an aspect ratio < 1.4 ($P = .006$), this is more likely due to a difference in sample size than an actual difference. Additionally, although one would expect high aspect ratios to lead to higher degrees of venous hypertension and, thereby, higher VCSSs, we found the

Table VI. Stent reinterventions stratified by aspect ratio groups

Stent reintervention	Aspect ratio			P value
	≥ 2 (n = 118; 50%)	1.41-1.99 (n = 64; 27%)	≤ 1.4 (n = 54; 23%)	
ISR	13 (11)	8 (13)	0 (0)	.03
SC	0 (0)	1 (2)	0 (0)	.26
ISR + SC	16 (14)	5 (8)	6 (11)	.51
Stent occlusion	3 (3)	1 (2)	0 (0)	.49
Total	32 (27)	15 (23)	6 (11)	.06

ISR, In-stent restenosis; SC, stent compression.

Data presented as number (%).

Rationale for reintervention was recurrence of quality of life-impairing clinical manifestations after stenting.

opposite. After stenting, there was improvement in the VCSS, GOS, and VAS for pain scores across all three aspect ratio groups at 6, 12, and 24 months after stenting.

Aspect ratio and QoL. For the entire cohort, the CIVIQ-20 score improved after stenting from 62 to 40 ($P < .0001$). This improvement was noted across all three groups after stenting without a significant difference between groups either at baseline or during follow-up after stenting. These findings are important given that the main goal of venous interventions is to improve QoL. A higher aspect ratio did not seem to result in a worse QoL.

Aspect ratio and stent outcomes. Overall, the primary, primary assisted, and secondary patency at 60 months was 77%, 99%, and 100%, respectively, which are similar to previously reported data.^{3,17} No differences were found in primary, primary assisted, or secondary patency between the three groups. At 60 months, for group I (aspect ratio, ≤ 1.4) the primary patency was 89%. For group II (aspect ratio, 1.41-1.99), primary patency was 80%. For group III (aspect ratio, ≥ 2), primary patency was 75.0%. Although there is a difference between the three groups, this was not statistically significant ($P = .85$). There was also no significant difference in the total number of reinterventions between the three groups. Additionally, although the group with an aspect ratio of ≥ 2 had more stent occlusions, the difference was not statistically significant ($P = .49$).

Study limitations. The relatively small size of the study groups, retrospective nature, and loss of patients to follow-up after treatment represent shortcomings and likely have a bearing on the findings. These drawbacks are difficult to counter. Although this study is one of the first of its kind to explore the impact of the iliac vein aspect ratio on outcomes, further corroboration is needed.

CONCLUSIONS

The native vein aspect ratio does not appear to determine the initial clinical presentation or QoL or impact the clinical or QoL outcomes after stenting in patients undergoing stenting for QoL-impairing symptoms of CIVO in whom conservative therapy has failed. After stenting, 97% of limbs had an aspect ratio of ≤ 1.4 , with none having an aspect ratio > 2 compared with 50% of limbs with a native vein aspect ratio of ≥ 2 . The IVUS-determined cross-sectional luminal area of the common femoral, external iliac, and common iliac segments should be used to confirm the diagnosis of CIVO and assess the adequacy of stenting.

The authors would like to thank Michael Owen, BS, for his assistance with data collection.

AUTHOR CONTRIBUTIONS

Conception and design: AJ

Analysis and interpretation: HB, AJ

Data collection: HB

Writing the article: HB, AJ

Critical revision of the article: HB, AJ

Final approval of the article: HB, AJ

Statistical analysis: HB

Obtained funding: Not applicable

Overall responsibility: AJ

DISCLOSURES

None.

REFERENCES

1. Lichtenberg M. Lumen Shape: a new measurement to consider in the treatment of iliofemoral venous outflow obstruction. *Endovascular Today*. 2018;6:9–11.
2. Raju S, Buck WJ, Crim W, Jayaraj A. Optimal sizing of iliac vein stents. *Phlebology*. 2018;33:451–457.
3. Jayaraj A, Noel C, Kuykendall R, Raju S. Long-term outcomes following use of a composite Wallstent-Z stent approach to iliofemoral venous stenting. *J Vasc Surg Venous Lymphat Disord*. 2021;9:393–400.e2.
4. Jayaraj A, Powell T, Raju S. Utility of the 50% stenosis criterion for patients undergoing stenting for chronic iliofemoral venous obstruction. *J Vasc Surg Venous Lymphat Disord*. 2021;9:1408–1415.
5. Jayaraj A, Buck W, Knight A, Johns B, Raju S. Impact of degree of stenosis in May-Thurner syndrome on iliac vein stenting. *J Vasc Surg Venous Lymphat Disord*. 2019;7:195–202.
6. Powell T, Raju S, Jayaraj A. Comparison between a dedicated venous stent and standard composite Wallstent-Z stent approach to iliofemoral venous stenting: Intermediate-term outcomes. *J Vasc Surg Venous Lymphat Disord*. 2023;11:82–90.e2.
7. Jayaraj A, Thaggard D, Lucas M. Technique of stent sizing in patients with symptomatic chronic iliofemoral venous obstruction—the case for intravascular ultrasound-determined inflow channel luminal area-based stenting and associated long-term outcomes. *J Vasc Surg Venous Lymphat Disord*. 2023;11:634–641.
8. Moreno AH, Katz AI, Gold LD, Reddy RV. Mechanics of distension of dog veins and other very thin-walled tubular structures. *Circ Res*. 1970;27:1069–1080.
9. Griffiths DJ. Steady fluid flow through veins and collapsible tubes. *Med Biol Eng*. 1971;9:597–602.
10. Raju S, Kuykendall R. Experimental analysis of aspect ratio in iliac vein stenosis. *J Vasc Surg Venous Lymphat Disord*. 2021;9:1041–10450.e1.
11. Jayaraj A, Raju S. Three-dimensional computed tomography venogram enables accurate diagnosis and treatment of patients presenting with symptomatic chronic iliofemoral venous obstruction. *J Vasc Surg Venous Lymphat Disord*. 2021;9:73–80.e1.
12. Jayaraj A, Crim W, Knight A, Raju S. Characteristics and outcomes of stent occlusion after ilioacaval stenting. *J Vasc Surg Venous Lymphat Disord*. 2019;7:56–64.
13. Jayaraj A, Fuller R, Raju S. Role of laser ablation in recalcitrant in-stent restenosis post iliofemoral venous stenting. *J Vasc Surg Cases Innov Tech*. 2021;7:298–301.
14. Jayaraj A, Fuller R, Raju S, Stafford J. In-stent restenosis and stent compression following stenting for chronic iliofemoral venous obstruction. *J Vasc Surg Venous Lymphat Disord*. 2022;10:42–51.
15. Launois R, Rebpi-Marty J, Henry B. Construction and validation of a quality of life questionnaire in chronic lower limb venous insufficiency (CIVIQ). *Qual Life Res*. 1996;5:539–554.
16. Launois R, Mansilha A, Jantet G. International psychometric validation of the chronic venous disease quality of life questionnaire (CIVIQ-20). *Eur J Vasc Endovasc Surg*. 2010;40:783–789.
17. Neglen P, Hollis KC, Olivier J, Raju S. Stenting of the venous outflow in chronic venous disease: long-term stent-related outcome, clinical, and hemodynamic result. *J Vasc Surg*. 2007;46:979–990.

Submitted Feb 5, 2024; accepted Apr 14, 2024.