

Comparison of intravascular ultrasound and magnetic resonance venography in the diagnosis of chronic iliac venous disease

Taimur Saleem, MBBS, FACS, Michael Lucas, MS, and Seshadri Raju, MD, FACS, Jackson, MS

ABSTRACT

Background: The diagnosis of chronic iliofemoral venous obstruction (CIVO) can be made with several different modalities. Intravascular ultrasound (IVUS) examination is the gold standard in the diagnosis of CIVO. However, being invasive, it should not be the initial examination to screen patients with CIVO. The aim of this report is to compare the performance of magnetic resonance venography (MRV) with IVUS examination in the diagnosis of CIVO.

Methods: From January 2016 to December 2020, the records of all patients who underwent preoperative MRV and then IVUS in the evaluation of CIVO were analyzed retrospectively.

Results: There were 505 patients who were evaluated by any modality for CIVO. Of these patients, 15% (78) were evaluated by MRV. Patients who had failed a trial of conservative therapy for at least 3 to 6 months and who had disabling and lifestyle-limiting symptoms of CIVO were selected to undergo further evaluation with MRV at the treating physician's discretion. For inclusion in analysis, technically satisfactory IVUS examination and MRV data were mandatory. Data was available for 60 common iliac vein (CIV) segments and 61 external iliac vein (EIV) segments for comparative analysis after appropriate exclusions. The mean age of the patients was 56 ± 15 years. The male to female ratio was 1:2. The distribution of patients across different CEAP classes was as follows: CEAP 3, 28%; CEAP 4, 62%; CEAP 5, 2%; and CEAP 6, 8%. Bland-Altman plots of the mean difference in area between IVUS examination and MRI were 74.1% for CIV and 56.9% for EIV. The sensitivity of MRV was 93% and 100%, and the specificity was 0% and 50% for CIV and EIV, respectively. The positive predictive value was 93% and 86%; the negative predictive value was 0 and 50% for CIV and EIV, respectively. Improvement was noted in clinical parameters (Venous Clinical Severity Score, visual analog pain scale, and grade of swelling) after IVUS examination and stenting after MRV. For the Venous Clinical Severity Score, the score improved from 6.0 ± 2.7 (before the procedure) to 4 ± 2.7 (after the procedure) ($P = .0001$).

Conclusions: There is dimensional disparity between MRV and IVUS examination in the diagnosis of symptomatic CIVO. MRV has a high sensitivity but low specificity when compared with IVUS examination and overestimates the severity of the stenosis in both the EIV and CIV. MRV is not a reliable diagnostic tool for iliac vein stenosis and should not be used for the definitive disposition of patients with CIVO. (J Vasc Surg Venous Lymphat Disord 2022;10:1066-71.)

Keywords: IVUS; Intravascular ultrasound; MRV; Magnetic resonance venography; Iliac vein stent; CIVO; Chronic iliofemoral venous obstruction

The importance of venous outflow obstruction in chronic venous disease has been increasingly recognized over the last two decades.¹ This has led to improvements in corresponding imaging modalities. The diagnosis of venous outflow obstruction can be made with several different modalities. Intravascular ultrasound (IVUS) examination is a highly sensitive diagnostic modality that provides real-time cross-sectional venous anatomy and defines the morphology of chronic iliofemoral venous obstruction (CIVO). In addition to guiding stent sizing, it provides vital information regarding the proximal and

distal extent for venous stenting.² IVUS examination is superior to venography in the diagnosis of CIVO.³ Venography underestimates and misses stenotic lesions compared with IVUS examination. It also misidentifies the location of the iliac-caval confluence when compared with IVUS examination.⁴ In the VIDIO trial, IVUS examination led to a revision in treatment plans in 57% of patients because venography failed to detect a significant lesion.⁵

However, IVUS examination may not be universally available, is an invasive modality and involves some

From The RANE Center for Venous and Lymphatic Diseases, Jackson.

Author conflict of interest: The authors declared the following potential conflicts of interest with respect to the research, authorship, and/or publication of this article: S.R.: US Patent, IVUS diagnostics; US Patent, Iliac vein stent design. The remaining authors declare no conflicts.

Additional material for this article may be found online at www.jvsvenous.org.
Correspondence: Taimur Saleem, MBBS, FACS, The Rane Center, 971 Lakeland Dr, Ste 401, Jackson, MS 39216 (e-mail: taimur@gmail.com).

The editors and reviewers of this article have no relevant financial relationships to disclose per the Journal policy that requires reviewers to decline review of any manuscript for which they may have a conflict of interest.

2213-333X

Copyright © 2022 by the Society for Vascular Surgery. Published by Elsevier Inc.

<https://doi.org/10.1016/j.jvs.2022.04.006>

radiation exposure. Thus, it should not be the initial test in patients with chronic venous insufficiency in whom CIVO is suspected. Ultrasound examination is a commonly used modality in CIVO, but tends to have significant dimensional disparity with IVUS examination.⁶ Other drawbacks of ultrasound examination include operator dependence, limited ability to visualize venous anatomy owing to obesity, vessel depth, tortuous venous trajectory, bowel gas, or acoustic shadowing. Thus, there is a need to identify a reliable, noninvasive imaging modality that can be used to select patients for intervention.^{1,3}

Some literature is now available on the comparison of computed tomography venography (CTV) and IVUS in patients with CIVO.^{1,7-9} However, reports comparing magnetic resonance venography (MRV) with IVUS examination in CIVO are limited.^{10,11} The aim of this report is to compare the performance of MRV with IVUS examination in the diagnosis of CIVO.

METHODS

Study design and setting. From January 2016 to December 2020, records of all patients who underwent IVUS examination and preoperative MRV in the evaluation of CIVO were included. This is a single-center study (three surgeons) at a specialty venous clinic at a tertiary care hospital. Informed consent was obtained from all patients for the described procedures and imaging. Institutional review board permission was granted for publication of de-identified patient data from the study.

Inclusion criteria. Patients who had failed a trial of conservative therapy for at least 3 to 6 months including compression stockings and who had disabling or lifestyle limiting symptoms of CIVO were selected to undergo further evaluation with MRV at the treating physician's discretion. For inclusion in analysis, technically satisfactory IVUS examination and MRV data were mandatory.

Exclusion criteria. Patients with acute deep venous thrombosis, chronic total occlusions, magnetic resonance imaging (MRI) unsafe metallic implants, severe claustrophobia, a contrast allergy to gadolinium, advanced renal disease, and less than 1 year of postprocedure follow-up data or loss to follow-up were excluded from the cohort. In addition, patients who had catheter-based venography or CTV performed as part of preoperative workup (instead of MRV) or who had missing borders of stenotic lesions on IVUS examination were also excluded from this study. The missing borders on IVUS examination are related to its lack of a centering mechanism, causing it to tilt at venous confluences.⁷

Data collection. Data were collected on the following variables: age, gender, type of venous lesion on IVUS examination (post-thrombotic, nonthrombotic), CEAP

ARTICLE HIGHLIGHTS

- **Type of Research:** Single-center retrospective study
- **Key Findings:** Magnetic resonance venography (MRV) has a high sensitivity but low specificity in the diagnosis of symptomatic obstructive chronic venous disease when compared with intravascular ultrasound (IVUS) examination.
- **Take Home Message:** There is dimensional disparity between MRV and IVUS examination in the diagnosis of symptomatic iliofemoral venous stenosis. MRV seems to overestimate the severity of the stenosis when compared with IVUS for both iliac venous segments (common iliac vein and external iliac vein). Because of the large variance in stenosis severity with MRV, IVUS examination should remain the final tool that determines the morphologic diagnosis of iliofemoral venous stenosis.

class, clinical presentation, IVUS planimetry, MRV measurements, follow-up, and complications.

MRV. Unenhanced time-of-flight of the pelvis was obtained using GE 1.5 Tesla MRI machine and then multiplanar rotatable maximum intensity projection reconstructions of the vasculature were performed of the pelvis data. Subsequently, approximately 20 mL of intravenous gadolinium contrast material was injected via venous access at the level of the antecubital fossa and coronal thin slice post contrast T1 weighted fat saturated sequences of the pelvis were obtained. Multiplanar rotatable maximum intensity projection reconstructions of the postcontrast T1 dataset were then performed. Imaging of abdomen and pelvis was started immediately after the injection of gadolinium without delay. On average, each MRV scan took approximately 30 minutes to complete (Supplementary Figs 1 and 2, online only). The MRV scans were read by one of the vascular radiologists on rotation (five radiologists) with venous experience who were blinded to the IVUS findings. The results were reported according to a uniform outline.

IVUS examination and procedural details. Details of IVUS examination have been described in detail previously.^{1,12} Briefly, ultrasound-guided venous access was obtained via the femoral vein in the mid to lower thigh. After the performance of single-plane venography, Visions PV .035 IVUS catheter (Phillips Volcano, San Diego, CA) was used to measure minimal luminal areas of external iliac vein (EIV) and common iliac vein (CIV). Venous stenosis was diagnosed on IVUS if the cross-sectional areas of EIV and CIV were less than 150 mm² (diameter 14 mm) and less than 200 mm² (diameter 16 mm), respectively. Such stenosis was treated in the setting of lifestyle-limiting symptoms after the failure of

Table I. Patient demographics (n = 61 patients)

| Characteristic | Mean ± SD (range) or No. (%) |
|----------------|------------------------------|
| Age, years | 56 ± 15 (18-80) |
| Male:female | 1:2 |
| Left:right | 4:2 |
| NIVL:PTS:mixed | 2:3:1 |
| CEAP class | |
| 0-2 | 0 |
| 3 | 17 (28) |
| 4 | 38 (62) |
| 5 | 1 (2) |
| 6 | 5 (8) |

CEAP, Clinical, Etiology, Anatomy and Pathophysiology; NIVL, non-thrombotic iliac vein lesion; PTS, post-thrombotic syndrome; SD, standard deviation.

conservative therapy with angioplasty and endovenous stenting.

Calculation of areas on IVUS examination and MRV.

Areas of less than 150 mm² and less than 200 mm² were considered as diagnostic of venous stenosis for EIV and CIV, respectively, for both MRV and IVUS examination. IVUS planimetry software was used to compute the area of the venous segment. The narrowest area point of the CIV and EIV was traced with an electronic pen.⁷ For the MRV, electronic calipers were used to measure the shortest diameter of the CIV and EIV at their narrowest point. This diameter was then converted to area for a circle (πr^2). Reverse conversion of the IVUS planimetry area into diameter for comparison produced a smaller area than the planimetry and hence was not used.⁶

Clinical parameters. Swelling was graded from 0 to 4 (grade 0, none; grade 1, pitting but overall nonobvious; grade 2, ankle edema; grade 3, gross involving the leg below the knee; grade 4, gross involving the whole limb). Patients were asked to rate their pain on a pain visual analog scale (VAS) from 0 to 10 in ascending order of increasing severity. The Venous Clinical Severity Score (VCSS) was also calculated at every follow-up visit. Data from the last follow-up visit were used for the purposes of statistical analysis.¹²

Statistical analysis. Statistical analysis was performed using a commercially available statistics program (SPSS version 26, IBM Corp, Armonk, NY). Pearson correlation was used to evaluate the correlation between MRV and IVUS examination. A Bland-Altman analysis was used to evaluate agreement between IVUS and MRV measurements. Measures of diagnostic assessment, including sensitivity, specificity, positive predictive value, negative predictive value, and accuracy were also determined. A *P* value of .05 or less was considered as significant.

RESULTS

From January 2016 to December 2020 (5 years), 5281 new patients were referred to our center for the evaluation of symptoms of chronic venous disease. Of these patients, 505 (9.6%) were evaluated by any imaging modality for CIVO after failure of conservative therapy. Of these 505 patients, 427 (85%) were evaluated by a contrast imaging modality other than MRV (CTV, venography). Seventy-eight patients (15%) had MRV performed followed by IVUS examination. Ten patients (13%) who had both IVUS examination and MRV were excluded because of missing borders on IVUS examination. Of these 10 patients with missing borders, 5 (50%) involved the CIV, 3 (30%) involved the EIV, and 2 (20%) involved both the CIV and EIV. Five patients (6%) had technically unsatisfactory MRV data. Two patients (3%) were lost to follow-up and had less than 1 year of follow-up data. Finally, data were available for 60 CIV segments and 61 EIV segments for comparative analysis after exclusions.

Demographics. The mean age of the patients was 56 ± 15 years. Male to female ratio was 1:2. Other demographic details are shown in Table I. The mean time frame between MRV and IVUS examination was 2.0 ± 1.5 months.

CEAP classification. Distribution of patients across different CEAP classes (Table I) was as follows: CEAP 3, 17 (28%); CEAP 4, 38 (62%); CEAP 5, 1 (2%); and CEAP 6, 5 (8%).

Area stenosis. Area stenosis was defined as an IVUS area of less than 200 mm² (diameter 16 mm) for the CIV 150 mm² (diameter 14 mm) for the EIV.² Using these values, more than 90% of CIV and more than 80% of EIV segments were noted to be stenotic by IVUS examination. However, 7% of CIV and 18% of EIV segments did not have stenosis per these criteria (Table II).

Comparison of IVUS examination and MRV. Bland-Altman plots of mean difference in area between MRV and IVUS were computed (Supplementary Fig 3, online only). The mean difference was 74.1% for the CIV and 56.9% for the EIV. Table III shows a comparison of the means of minimal areas for the EIV and CIV noted on MRV and IVUS examination. For all four segments (right CIV, right EIV, left

Table II. Comparison of magnetic resonance venography (MRV) vs intravascular ultrasound (IVUS) examination

| Control groups | CIV (n = 60) | EIV (n = 61) |
|---|--------------|--------------|
| IVUS stenosis positive control ^a | 56 (93) | 50 (82) |
| IVUS stenosis negative control ^b | 4 (7) | 11 (18) |

^aLumen area/diameter: <200 mm²/16 mm for CIV, <150 mm²/14 mm for EIV.
^bLumen area/diameter: >200 mm²/16 mm for CIV, >150 mm²/14 mm for EIV.
 CIV, Common iliac vein; EIV, external iliac vein.
 Values are reported as number (%).

Table III. Comparison of means of minimal areas for external iliac vein (EIV) and common iliac vein (CIV) noted on magnetic resonance venography (MRV) and intravascular ultrasound (IVUS) examination

| Venous segment | MRV area (mm ²) | IVUS area (mm ²) | P value |
|----------------|-----------------------------|------------------------------|--------------|
| L CIV | 57 ± 60 | 118 ± 89 | .0009 |
| L EIV | 87 ± 39 | 126 ± 47 | .0001 |
| R CIV | 81 ± 39 | 126 ± 27 | .001 |
| R EIV | 71 ± 40 | 113 ± 30 | .0005 |

CIV, Common iliac vein; EIV, external iliac vein; L, left; R, right. Values are mean ± standard deviation. Bold face indicates significant P values.

CIV, and left EIV), the means measured by MRV were smaller than IVUS areas with statistically significant P values for each association. Spearman correlations between IVUS examination and MRV for CIV and EIV were as follows: right CIV (r = 0.06; P = .8), right EIV (r = 0.34, P = .2), left CIV (r = -0.03, P = .8), and left EIV (r = 0.49, P = .002).

Diagnostic statistics. Table IV details the true and false positives in this patient population. There were four true negatives for the EIV and none for the CIV. There were four false positives each for the CIV and the EIV. False positives occurred because cross-sectional areas were smaller with MRV when compared with corresponding areas observed on IVUS examination. There were four false negatives for the CIV and none for the EIV. Table V provides further details of diagnostic accuracy including the sensitivity, specificity, positive predictive value, negative predictive value, and accuracy of MRV when compared with IVUS examination. The sensitivity was 93% and 100%, and the specificity was 0 and 50% for the CIV and the EIV, respectively. The positive predictive value was 93% and 86%, and the negative predictive value was 0 and 50% for the CIV and the EIV, respectively. The overall accuracy was 86% and 93% for the CIV and the EIV, respectively.

Clinical parameters. Overall, there was improvement noted in clinical parameters (VCSS, VAS pain, and edema grade) after IVUS and stenting after MRV investigation (Table VI). The mean VCSS score improved from 6 ± 2.7 to 4 ± 2.7 (P = .0001). The mean visual analog pain score

improved from 5.0 ± 2.7 to 3.0 ± 3.0 (P = .0001). The mean grade of swelling improved from 3.0 ± 0.9 to 2.0 ± 1.2 (P = .0001).

Follow-up. The median follow was 44 months. The mean follow-up was 56 ± 15 months (range, 12-75 months).

DISCUSSION

This study showed that MRV lacks dimensional parity with IVUS examination in the diagnosis of CIVO. Therefore, its clinical usefulness is limited. It has a high sensitivity but low specificity when compared with IVUS examination. Although it certainly captures patients with iliofemoral venous stenosis, it seems to overestimate the severity of the stenosis when compared with IVUS for both venous segments (CIV and EIV). Because of the large variance in stenosis severity observed with MRV, IVUS should remain the final tool that determines the diagnosis of CIVO and thus the invasive clinical treatment of patients with CIVO.⁷

MRV is a noninvasive imaging modality that uses contrast (gadolinium) and does not use ionizing radiation. In contrast with IVUS examination, MRV does not have missing venous borders. Approximately 15% to 20% patients who undergo IVUS examination have missing or incomplete venous borders.⁷ Unlike duplex ultrasound examination, there is lack of operator dependence with MRV. Furthermore, unlike venography, it has an internal scale of reference. It provides multiple data points related to the various venous system segments and can show the direction of flow as well as the presence of collaterals. It can be considered in pregnancy.^{3,13,14} Postprocessing of MRV data can yield additional information.¹⁴

However, the use of MRV is prohibitive in patients with an allergy to gadolinium, advanced renal disease, or the presence of certain metallic implants that are deemed MRI unsafe. The signal can be degraded by motion or flow artifacts. Similarly, signal quality may deteriorate in the presence of very tortuous venous anatomy.³ There is also some evidence that the degree of the venous compression can fluctuate based on the hydration status of the patient.¹⁵ On average, an MRV examination takes longer

Table IV. Magnetic resonance venography (MRV) true and false positives and negatives compared with intravascular ultrasound (IVUS) examination

| Diagnostic MRV stenosis threshold | No. | True positives | True negatives | False positives | False negatives |
|--|-----|------------------|----------------|-----------------|-----------------|
| CIV area <200 mm ² (diameter <16 mm) | 58 | 50 (86) | 0 | 4 (7) | 4 (7) |
| EIV area <150 mm ² (diameter <14 mm) | 56 | 48 (86) | 4 (7) | 4 (7) | 0 |
| CIV area <200 mm ² (diameter <16 mm) or EIV area <150 mm ² (diameter <14 mm) | 61 | 57 (93) | 0 | 4 (7) | 0 |
| P values | | CIV .09, EIV .09 | EIV .04 | CIV .9, EIV .9 | CIV .04 |

CIV, Common iliac vein; EIV, external iliac vein. Bold face indicates significant P values.

Table V. Diagnostic measures of magnetic resonance venography (MRV) assessment of iliac venous stenosis

| Diagnostic MRV stenosis threshold | NO. | Sensitivity (%) | Specificity (%) | Positive predictive value (%) | Negative predictive value (%) | Accuracy (%) |
|--|-----|-----------------|----------------------|-------------------------------|-------------------------------|----------------|
| CIV area <200 mm ² (diameter <16 mm) | 58 | 93 | 0 | 93 | 0 | 86 |
| EIV area <150 mm ² (diameter <14 mm) | 56 | 100 | 50 | 86 | 50 | 93 |
| CIV area <200 mm ² (diameter <16 mm) or EIV area <150 mm ² (diameter <14 mm) | 61 | 100 | 0 | 93 | 0 | 93 |
| <i>P</i> values | | CIV .04 | EIV <.0001 | EIV .2, CIV .9 | EIV <.0001 | EIV .9, CIV .2 |

CIV, Common iliac vein; *EIV*, external iliac vein.
Bold face indicates significant *P* values.

than a CTV examination. Cost, delay in scheduling, and general availability are other issues that require consideration.

Using IVUS examination as a gold standard, the sensitivity of MRV in this study approached 93% to 100% and the specificity was 0% to 50%. The positive predictive value and negative predictive value of MRV in the diagnosis of CIVO were 86% to 93% and 0% to 50%, respectively. This finding is similar to a prior study where MRV, when compared with IVUS examination, was noted to have a sensitivity and specificity of 100% and 22.7%, respectively.¹⁰

In the current study, gadolinium contrast was used for the performance of MRV. Kusiak and Budzyński¹¹ have compared contrast-enhanced MRI (CE-MRI), non-contrast-enhanced MRI (NCE-MRI) and IVUS examination in a prior study. High correlation was observed on target vein section areas between CE-MRI and NCE-MRI (spearman correlation statistic: 0.87-0.97; $P < .001$), but not with IVUS examination (Spearman correlation statistic, -0.28 to 0.47 ; $P > .05$). Percentage difference in vein section areas between CE-MRI/NCE-MRI and IVUS examination was 27% to 60%.¹¹ In our study, Bland-Altman plots of mean difference in area between IVUS examination and MRV were 74.1% and 56.9% for the CIV and the EIV, respectively. MRV areas were significantly smaller when compared with IVUS examination.

In another study, a comparison of noncontrast balanced steady-state free precession MRI was drawn against intravenous digital subtraction angiography. Noncontrast MRI overdiagnosed chronic intraluminal webs but underdiagnosed stenosis.^{16,17}

MRV seems to be similar to duplex ultrasound examination in its comparison with IVUS examination. Both modalities demonstrate dimensional disparity with IVUS examination and show correspondingly smaller areas than IVUS examination. In a study including 382 limbs, duplex cross-sectional areas were smaller when compared with IVUS examination (Bland-Altman means of 54 mm² and 34 mm² for the CIV and the EIV, respectively).⁶ In contrast, CTV seems to be more reliable

than with MRV or duplex in the diagnostic workup of CIVO. The mean CTV cross-sectional area difference compared with IVUS examination was only 2.5% and 7.3% for the CIV and the EIV, respectively, in one study.⁴ Therefore, CTV may be the favored or preferred pre-IVUS test, if one is performed, based on its better dimensional parity with IVUS examination.⁶ CTV can also be used in the preoperative planning of patients with CIVO. It can predict stent diameters and stent lengths with a reasonable degree of accuracy.¹

An additional consideration worth mentioning is the cost associated with MRV, CTV, and IVUS examination. Also, IVUS examination requires special equipment, usually a catheterization laboratory or hybrid room, with its attendant costs.

Improvement was noted in clinical parameters (VCSS, VAS pain, and edema grade) after stenting was performed after MRV. This finding is similar to a prior study where endovascular management produced good clinical outcomes when intervention followed the performance of MRV.¹⁸

CIVO is an example of a permissive lesion; this means that the lesion is widely prevalent in the general population, but may not produce symptoms until a secondary insult comes into play. This secondary insult can include conditions such as trauma, infection, thrombosis, or reflux.¹⁹ The high sensitivity of MRV depends on the high prevalence of obstructive chronic venous disease in symptomatic patients with CIVO.⁴

Table VI. Clinic improvement in patients who had intravascular ultrasound (IVUS) examination and intervention performed after magnetic resonance venography (MRV)

| Clinical parameter | Preintervention | Postintervention | <i>P</i> value |
|--------------------|-----------------|------------------|----------------|
| VAS pain | 5 ± 2.7 | 3 ± 3 | .0001 |
| Swelling | 3 ± 0.9 | 2 ± 1.2 | .0001 |
| VCSS | 6 ± 2.7 | 4 ± 2.7 | .0001 |

VAS, Visual analogue scale; VCSS, Venous Clinical Severity Score.
Bold face indicates significant *P* values.

A general algorithm for the evaluation of patients with CIVO has been described by the authors previously and can be referred to for guidance.³ CTV seems to perform better than MRV and should be considered in the workup of patients with CIVO who have failed conservative therapy.

Study limitations. The main limitations of this study include its retrospective nature and small sample size. The choice of MRV as part of workup for CIVO was at the discretion of the physician. As mentioned elsewhere in this article, IVUS examination has its own set of limitations that should also be kept in mind.^{3,6} There is inherent selection bias in the study because patients who were highly symptomatic and who had failed conservative therapy were selected to undergo further testing with an MRV study; hence, the yield was high. Recently, Chen et al¹⁸ published their preliminary experience with evaluation of hemodynamic parameters, such as flow rate in iliac vein compression syndrome using MRI. In our study, hemodynamic parameters were not assessed. Area was calculated using planimetry software for IVUS examination and from diameter measurements for MRV. Because veins are elliptical structures, this difference in comparison metric is a potential source of bias and acknowledged. Although physiological noise from respirations was accounted for, physiological parameters such as timing of heart beat were not. The MRV results may have been affected by that. However, MRV studies that were technically unsatisfactory were excluded.

CONCLUSIONS

There is dimensional disparity between MRV and IVUS examination in the diagnosis of symptomatic CIVO. MRV has a high sensitivity but low specificity when compared with IVUS examination. It tends to overestimate the severity of the stenosis in both the EIV and CIV. MRV is not a reliable diagnostic tool for CIVO and should not be used for the definitive disposition of patients with CIVO.

AUTHOR CONTRIBUTIONS

Conception and design: TS, SR

Analysis and interpretation: TS, ML, SR

Data collection: ML

Writing the article: TS, ML, SR

Critical revision of the article: TS, ML, SR

Final approval of the article: TS, ML, SR

Statistical analysis: ML

Obtained funding: Not applicable

Overall responsibility: TS

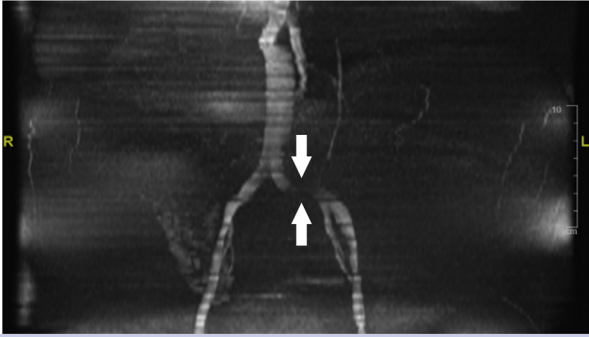
REFERENCES

1. Jayaraj A, Raju S. Three-dimensional computed tomography venogram enables accurate diagnosis and treatment of patients

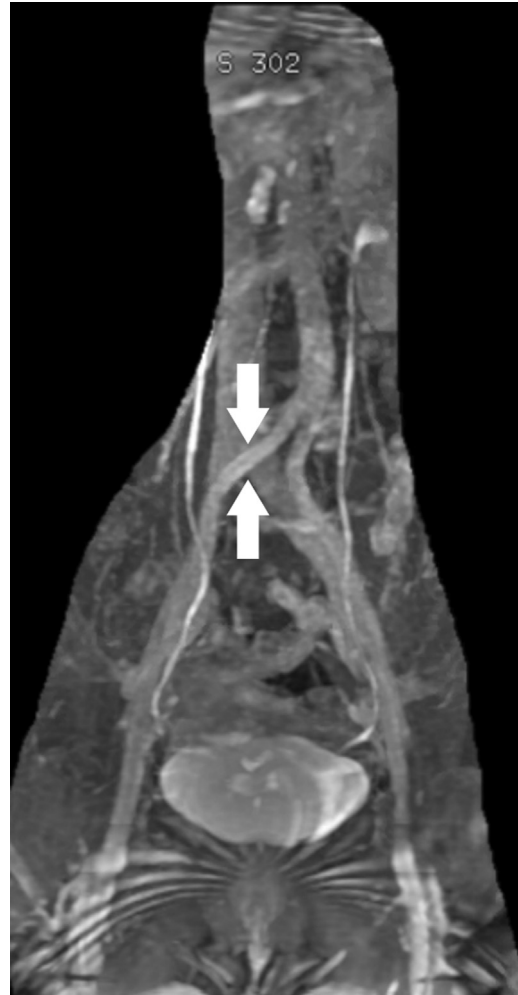- presenting with symptomatic chronic iliofemoral venous obstruction. *J Vasc Surg Venous Lymphat Disord* 2021;9:73-80.e1.
2. Saleem T, Knight A, Raju S. Diagnostic yield of intravascular ultrasound in patients with clinical signs and symptoms of lower extremity venous disease. *J Vasc Surg Venous Lymphat Disord* 2020;8:634-9.
3. Saleem T, Raju S. Comparison of intravascular ultrasound and multidimensional contrast imaging modalities for characterization of chronic occlusive iliofemoral venous disease: a systematic review. *J Vasc Surg Venous Lymphat Disord* 2021;9:1545-56.e2.
4. Montminy ML, Thomasson JD, Tanaka GJ, Lamanilao LM, Crim W, Raju S. A comparison between intravascular ultrasound and venography in identifying key parameters essential for iliac vein stenting. *J Vasc Surg Venous Lymphat Disord* 2019;7:801-7.
5. Gagne PJ, Tahara RW, Fastabend CP, Dzieciuchowicz L, Marston W, Vedantham S, et al. Venography versus intravascular ultrasound for diagnosing and treating iliofemoral vein obstruction. *J Vasc Surg Venous Lymphat Disord* 2017;5:678-87.
6. Raju S, Walker W, Noel C, Kuykendall R, Powell T, Jayaraj A. Dimensional disparity between duplex and intravascular ultrasound in the assessment of iliac vein stenosis. *Vasc Med* 2021;26:549-55.
7. Raju S, Walker W, Noel C, Kuykendall R, Jayaraj A. The two-segment caliber method of diagnosing iliac vein stenosis on routine computed tomography with contrast enhancement. *J Vasc Surg Venous Lymphat Disord* 2020;8:970-7.
8. Rossi FH, Kambara AM, Rodrigues TO, Rossi CBO, Izukawa NM, Pinto IMF, et al. Comparison of computed tomography venography and intravascular ultrasound in screening and classification of iliac vein obstruction in patients with chronic venous disease. *J Vasc Surg Venous Lymphat Disord* 2020;8:413-22.
9. Shammam NW, Shammam GA, Jones-Miller S, Radaideh Q, Winter AR, Shammam AN, et al. Predicting iliac vein compression with computed tomography angiography and venography: correlation with intravascular ultrasound. *J Invasive Cardiol* 2018;30:452-5.
10. Massenbourg BB, Himel HN, Blue RC, Marin ML, Faries PL, Ting W. Magnetic resonance imaging in proximal venous outflow obstruction. *Ann Vasc Surg* 2015;29:1619-24.
11. Kusiak A, Budzyński J. Usefulness of non-contrast-enhanced magnetic resonance imaging prior to venous interventions. *Postepy Kardiologii Interwencyjnej* 2019;15:338-44.
12. Saleem T, Powell T, Raju S. Iliofemoral venous stenting in patients with central neuromuscular disorders. *J Vasc Surg Venous Lymphat Disord* 2022;103:626-32.
13. Radaideh Q, Patel NM, Shammam NW. Iliac vein compression: epidemiology, diagnosis and treatment. *Vasc Health Risk Manag* 2019;15:115-22.
14. Zucker EJ, Ganguli S, Ghoshhajra BB, Gupta R, Prabhakar AM. Imaging of venous compression syndromes. *Cardiovasc Diagn Ther* 2016;6:519-32.
15. Fereydooni A, Stern JR. Contemporary treatment of May-Thurner syndrome. *J Cardiovasc Surg (Torino)* 2021;62:447-55.
16. Silicckas J, Black SA, Phinikaridou A, Cwozdz AM, Smith A, Saha P. Use of computed tomography and magnetic resonance imaging in central venous disease. *Methodist Debaquey Cardiovasc J* 2018;14:188-95.
17. Helyar VG, Gupta Y, Blakeway L, Charles-Edwards G, Katsanos K, Karunanithy N. Depiction of lower limb venous anatomy in patients undergoing interventional deep venous reconstruction-the role of balanced steady state free precession MRI. *Br J Radiol* 2018;91:20170005.
18. Chen ZH, Huang Y, Wang LP, Peng MY, Li C, Huang W. Preliminary study of hemodynamics of iliac vein compression syndrome using magnetic resonance imaging. *J Vasc Surg Venous Lymphat Disord* 2022;10:131-8.e3.
19. Raju S, Neglen P. High prevalence of non-thrombotic iliac vein lesions in chronic venous disease: a permissive role in pathogenicity. *J Vasc Surg* 2006;44:136-43; discussion: 144.

Submitted Feb 16, 2022; accepted Apr 11, 2022.

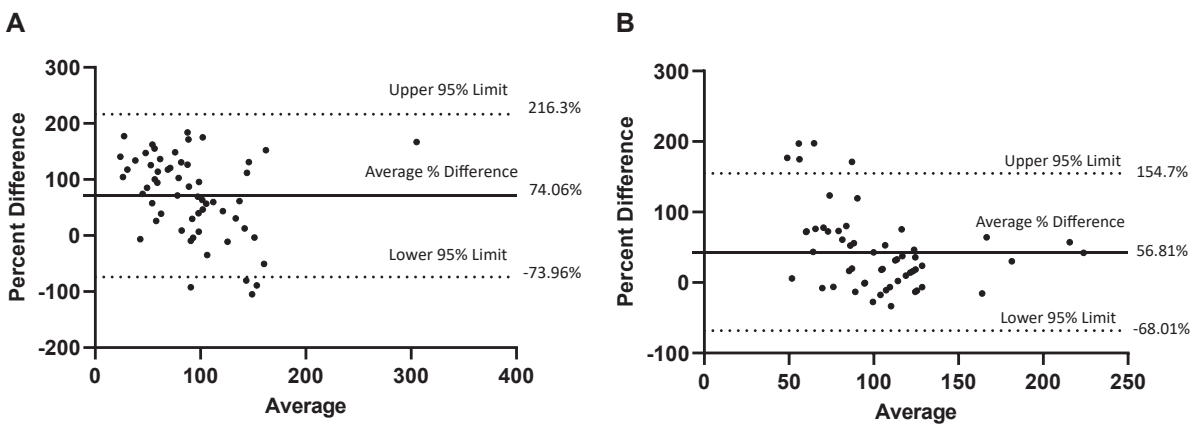
Additional material for this article may be found online at www.jvsvenous.org.



Supplementary Fig 1 (online only). Magnetic resonance venography (MRV) showing diffuse narrowing of the left common iliac vein (CIV). There is associated turbulent flow/heterogeneously diminished flow signal in the left common iliac vein on this time-of-flight sequence (arrows).



Supplementary Fig 2 (online only). Time-of-flight magnetic resonance venography (MRV) sequence showing course of the right common iliac artery as it crosses the left common iliac vein (CIV) causing venous compression syndrome (arrows).



Supplementary Fig 3 (online only). Bland-Altman plot of mean difference in caliber of 74.1% for common iliac vein (CIV; **A**) and 56.9% for external iliac vein (EIV; **B**) by magnetic resonance venography (MRV) compared with intravascular ultrasound (IVUS) examination.