

The role and principles of stenting in acute iliofemoral venous thrombosis

Efthymios D. Avgerinos, MD, FEBVS,^{a,b} Stephen Black, MD,^c Marie Josee van Rijn, MD,^d and Houman Jalaie, MD,^e Athens, Greece; London, United Kingdom; Rotterdam, The Netherlands; and Aachen, Germany

ABSTRACT

Catheter-directed interventions for acute iliofemoral deep venous thrombosis (DVT) have been increasingly used over the past 15 years to target severe symptomatology and prevention of post-thrombotic syndrome incidence or reduce its severity if it were to develop. Aside from successful thrombus removal, adjunctive stents are frequently required to treat an uncovered lesion or significant residual thrombus to ensure quality of life improvement besides retarding DVT recurrence and post-thrombotic syndrome. As the evidence is mounting, the need and role for stenting, as well as the principles of an optimal technique, in the acute DVT setting are now better understood. Accumulating experience appears to favor stenting in the acute setting. The diameter of the stent, the length, the extent of overlapping, and the landing zones are crucial determinants of a successful durable outcome. This article endeavors to guide the interventionalist on stenting when encountering a patient with acute symptomatic iliofemoral DVT with concerns of quality of life impairment. (J Vasc Surg Venous Lymphat Disord 2024;12:101868.)

Keywords: Acute deep vein thrombosis; Intravascular ultrasound; Thrombectomy; Thrombolysis; Venous stent

Deep venous thrombosis (DVT) is a common disease with a growing incidence. It recurs frequently and is associated with reduced survival, risk of developing post-thrombotic syndrome (PTS), and substantial health care costs.¹⁻⁴ Iliofemoral DVT, in particular, is associated with an up to 50% risk of developing PTS, either because spontaneous recanalization is partial or none, or because the valves have been permanently damaged by the thrombus and associated inflammation.⁵⁻⁷ In clinical terms, PTS can be a very debilitating condition despite adequate anticoagulation and appropriate compression.⁴⁻¹⁰

Anticoagulation globally remains the standard of care for treatment, preventing DVT propagation, recurrence, and pulmonary embolism.⁴ Anticoagulation, however, does not dissolve thrombus but rather prevents extension while intrinsic thrombolytic pathways are slowly taking over. Therefore, interventional treatments to rapidly

remove the clot and prevent associated valve damage and residual venous obstruction have always been attractive. Catheter-directed interventions (CDIs) for acute iliofemoral DVT have been increasingly used over the past 15 years targeting severe symptomatology and PTS prevention or severity reduction.¹⁰⁻¹⁴

Aside from successful thrombus removal, adjunctive stents are frequently essential to cover an underlying lesion or residual thrombus to prevent DVT recurrence. As the evidence is mounting, the need and role for stenting, as well as the principles of an optimal technique, in the acute DVT setting are now better understood.

PATIENT SELECTION FOR ACUTE DVT INTERVENTION

An intervention should generally not be considered for femoropopliteal DVT; however, based on the available data, it is noted that PTS rates are still high in these patients, suggesting that further work is needed. Among those with an acute iliofemoral DVT (typically <2-4 weeks), eligibility for a CDI includes patients with a threatened limb (phlegmasia cerulea dolens) or those with severe symptomatology (pain and swelling, difficulty walking). Although the threatened-limb population should not be delayed, the symptomatic ones can be observed for a couple of days on anticoagulation and compression before any decision to intervene, as conservative treatment may sometimes allow complete symptom resolution. It is important to assess the symptoms on exertion.

For those whose symptoms persist, there is a good indication for intervention. The benefits can only be enjoyed by those who are physically active and have a reasonable life expectancy (≥ 5 years) to optimize benefit and justify

From the Department of Vascular Surgery, Attikon Hospital, University of Athens,^a and the Athens Medical Center, Clinic of Vascular and Endovascular Surgery,^b Athens; the Department of Vascular Surgery, Guy's and St Thomas' Hospital and Kings College, London^c; the Department of Vascular and Endovascular Surgery, Erasmus University Medical Center, Rotterdam^d; and the Department of Vascular Surgery, European Venous Center, University Hospital RWTH Aachen, Aachen.^e

Correspondence: Efthymios D. Avgerinos, MD, FEBVS, Athens Medical Center, Kifisias 56 & Delfon, Marousi, Athens, Greece 151 25 (e-mail: eavgerinos@vascularhealth.gr).

The editors and reviewers of this article have no relevant financial relationships to disclose per the JVS policy that requires reviewers to decline review of any manuscript for which they may have a conflict of interest.

2213-333X

Copyright © 2024 The Author(s). Published by Elsevier Inc. on behalf of the Society for Vascular Surgery. This is an open access article under the CC BY-NC-ND license (<http://creativecommons.org/licenses/by-nc-nd/4.0/>).

<https://doi.org/10.1016/j.jvs.2024.101868>

the costs and risks of intervention.¹⁴⁻¹⁶ A recent subanalysis of the ATTRACT trial indicated that higher presenting clinical severity predicts greater benefits for a pharmacomechanical catheter intervention (vs anticoagulation alone) on PTS severity and quality of life at 2 years.¹⁵

The type of CDI, purely thrombolytic, pharmacomechanical, or mechanical thrombectomy, alone can be primarily guided by the bleeding risk assessment and secondarily by physician expertise and institutional logistics (see the "Thrombus removal" section). As a principle, patients at bleeding risk (eg, recent surgery or trauma) should not be offered thrombolytic therapy but rather anticoagulation alone or percutaneous mechanical thrombectomy options that can be performed with no lytic exposure.

Thrombus removal. Contemporary practice offers several technical alternatives for thrombus removal, largely divided into thrombolytic and nonthrombolytic techniques, though in selected cases, a combination may be optimal. Thrombectomy techniques have recently evolved toward thrombolytic-free interventions, altering the safety profile and the complex hospital logistics (eg, need for intensive care unit stay). Contemporary practice has shifted toward a single-session mechanical intervention without intensive care unit stay. An increasing number of thrombectomy technologies are available in the market, but an analysis of each of them is beyond the scope of this article.^{15,17-24}

Yet, thrombolytic catheters have a low profile, and lytics can reach and clear more distal and collateral venous tributaries. Thrombolytics, for patients at low bleeding risk, still remain relevant and should be considered in certain clinical scenarios: (1) to establish inflow in an "ascending" thrombosis (eg, patient with iliofemoral and tibial/popliteal DVT), (2) in any patient whose collateral ilio caval flow is thrombosed and vital to be established (eg, inferior vena cava [IVC] aplasia), (3) in-stent thrombosis, (4) in caval filter thrombosis, and (5) in extensive DVT to achieve a cleaner vein before embarking for mechanical thrombectomy or after debulking a large amount of thrombus with mechanical thrombectomy, and there is still significant residual thrombus.

In principle, the thrombectomy technique should be individualized based on the patients' comorbidities and "DVT anatomy" and the physician's best clinical judgment. There is no ideal device or technique: aspiration/mechanical thrombectomy can bail out a failed thrombolytic technique and thrombolysis can bail out a failed aspiration thrombectomy. A successful thrombus removal is the one with >90% extraction in the iliofemoral segments assessed with multiplanar venography and intravascular ultrasound (IVUS) imaging ("clean vein hypothesis") to provide optimal inflow (through the femoral and deep femoral veins) to the iliac segment. High thrombus removal rates minimize the risk of early

rethrombosis or later PTS.²⁵⁻²⁸ It needs to be clarified that this >90% threshold and statements derive mainly from thrombolytic or pharmacomechanical thrombectomy studies and experts' opinion; thus, their application in mechanical thrombectomy is still controversial because no prospective study with a control group has been completed. It is otherwise now clear that complete lysis on venography does not equate to complete lysis on IVUS imaging (that was not typically used in the aforementioned studies).

To stent or not to stent?. After successful thrombus removal, it is critical to decide whether a stent needs to be placed, and if so, to decide on the diameter, the length, and the landing zones.

While in the early years, stenting rates were low (<50%), accumulating experience favors stenting, most likely exceeding 50% of intervened patients.^{4,27,29-33} The rationale for stenting is to treat the underlying precipitating factor that provoked the DVT (typically an iliac vein compression—May-Thurner lesion)³⁴⁻³⁶ or cover residual acute and chronic thrombotic-collagenous material that creates a significant stenosis (>50%) area reduction (frequently corresponding to >70% diameter stenosis). This derives however from studies on chronic obstructive disease.³⁷ There are no trials offering direct comparison between stenting and no stenting after early thrombus removal; however, experts' opinion and indirect evidence are supporting this practice (Table).^{29,38-40} It follows the general principle of providing good inflow and good outflow in any deep venous intervention restoring iliac vein patency.

A U.S. multicenter venous registry reported 1-year venous patency that was significantly better in limbs treated with iliac stents (74%) than in limbs without stent placement (53%; $P < .001$).²⁹ The major randomized trials CaVenT and ATTRACT, despite that left-sided DVTs dominated, did not have a high stent usage rate after thrombolysis (17% and 28%, respectively, in their mixed femoropopliteal and iliofemoral DVT population). This has been criticized as a major limiting factor to show superiority of catheter interventions.^{33,41-44} This criticism though can be defended on the basis of a different population and practice than those seen in the real world. In real world practice, patients with DVT are first anticoagulated, and only those whose symptoms or thrombus extent worsens are referred for thrombus removal. Hence, they are preselected for factors that predict the presence of a lesion, hence the high observed stenting rates.

Two novel dedicated venous stents trials, ABRE (ABRE stent; Medtronic) and VIVO (Zilver Vena stent; Cook Medical), have included patients with acute DVT. The ABRE trial included 33 patients and demonstrated 100% patency at 1 year and significant quality of life scores' improvement.⁴⁵ The VIVO trial included 59 patients

Table. PICO (patients, intervention, comparison, and outcome) data on the effect of adjunctive stenting after acute deep vein thrombosis (DVT) thrombolysis/thrombectomy on study outcomes

Investigator	Population	Intervention	Comparison	Outcomes	Study design
Mewissen et al ²⁹	287 patients (303 limbs) with symptomatic iliofemoral or femoropopliteal DVT	Catheter thrombolysis without stenting	Catheter thrombolysis with adjunctive stenting (n = 105 limbs, 33%)	At 1 year, 74% of limbs treated with stent placement remained patent as compared with 53% of limbs without stent placement ($P < .001$).	Retrospective cohort/registry
Stanley et al ³⁸	52 patients with symptomatic iliofemoral or femoropopliteal DVT	Catheter thrombolysis or PMT without stenting	Catheter thrombolysis or PMT with adjunctive stenting (n = 33 patients, 63%)	Overall patency 94% at an average follow-up of 3.8 years. Rethrombosis occurred in 2 of 21 nonstented patients and 1 of 33 stented patient.	Retrospective cohort
Avgerinos et al ³⁹	93 patients (118 limbs) with symptomatic iliofemoral DVT	Catheter thrombolysis or PMT without stenting	Catheter thrombolysis of PMT with adjunctive stenting (n = 52 patients, 56%)	Overall patency and PTS at 3 years were 72.1% and 28.4%, respectively. Stent use was not a predictor of immediate failure, DVT recurrence, or PTS at 3 years	Retrospective cohort
Jayaraj et al ⁴⁰	65 patients (69 limbs) with symptomatic iliofemoral DVT	PMT or mechanical thrombectomy without stenting	PMT or mechanical thrombectomy with adjunctive concurrent stenting (n = 23 limbs, 33.3%)	At 24 months, the native iliofemoral segment had a patency of 72%, whereas the concurrent stented segment had a primary patency of 87%.	Retrospective cohort

PMT, Pharmacomechanical thrombectomy; *PTS*, post-thrombotic syndrome.
Studies provided are the ones where a known number of population were concurrently stented, and there is a reported comparison against the nonstented population.

with acute DVT; the total mixed cohort of 243 patients had 89.9% primary patency at 1 year.⁴⁶ A systematic review of deep venous stenting in acute DVT identified 27 studies (542 patients), including 3 randomized trials. All patients included had undergone lysis, venoplasty, and stenting. The overall patency rates were 87.8% over a follow-up period of 12-19.7 months. PTS was assessed in 26 of 27 studies with an observed rate of 14.6%.⁴⁷

A more recent study by Jayaraj et al⁴⁰ challenges this concept. In a series of 65 patients (69 limbs) with acute symptomatic iliofemoral DVT with quality of life

impairment who underwent pharmacomechanical thrombectomy (16 limbs had additional catheter directed thrombolysis) with a goal of IVUS imaging determined restoration of inline flow (with or without adjunctive stenting), only 33% underwent intraoperative stenting and an additional 14% underwent delayed stenting at a median follow-up time of 4 months. At 24 months, the native (unstented) iliofemoral segment had a patency of 72%, whereas the concurrent stented segment had a primary patency of 87%.⁴⁰ Although the patency of the unstented population appears

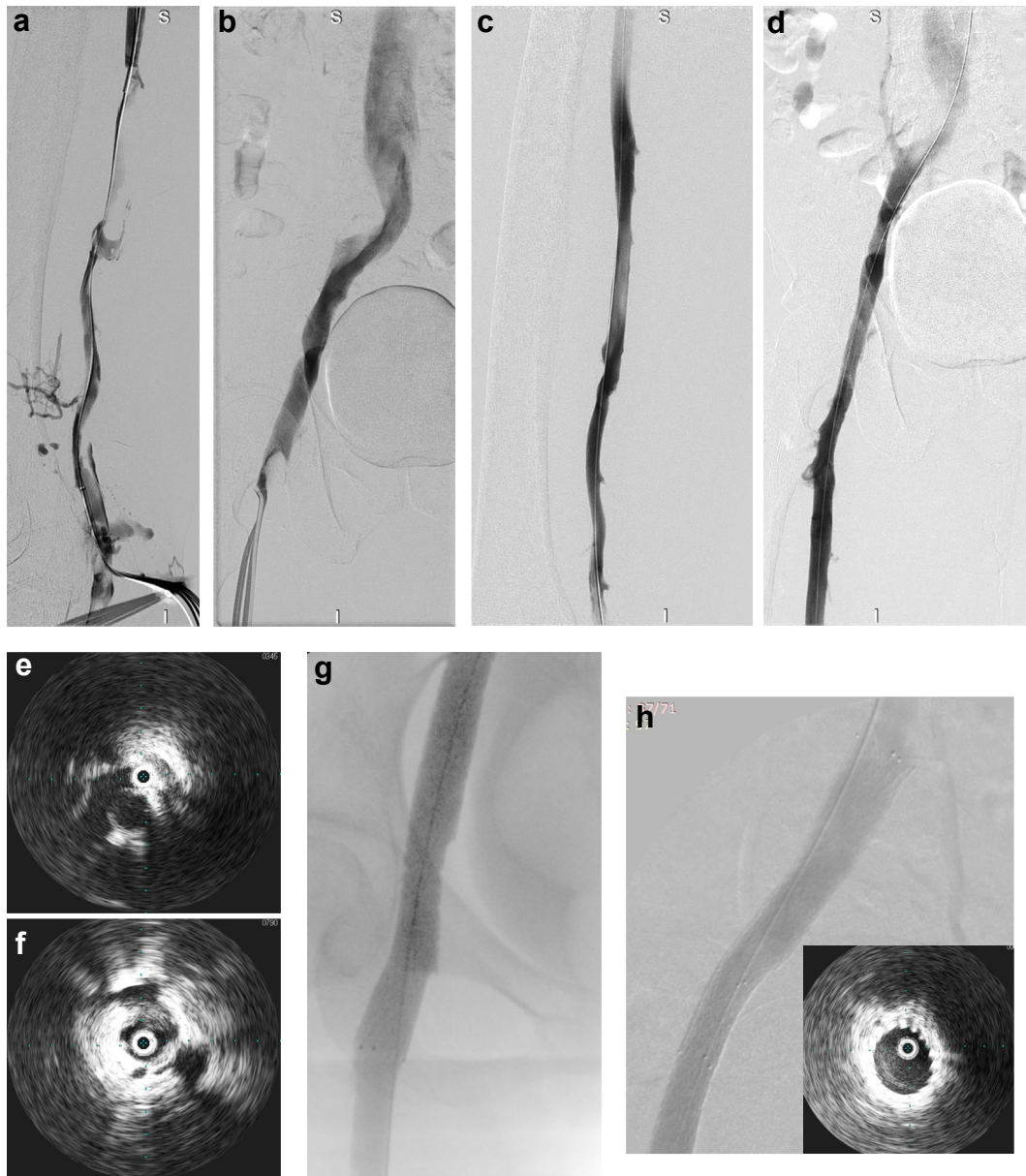

Fig 1. Iliofemoral deep vein thrombosis (DVT) intervention, thrombectomy, and stenting. **a**, Left popliteal access with the patient in a prone position, venogram indicating femoral vein thrombus. **b**, Venogram through the catheter positioned in the distal common femoral vein (CFV), indicating some thrombus in the CFV and a diseased common iliac segment. **c,d**, Post-thrombectomy venogram using the ClotTriever Thrombectomy System (INARI Medical); the vast majority of thrombus has been removed. **e,f**, Intravascular ultrasound (IVUS) imaging confirms disease/compression at the proximal common iliac vein and disease/residual thrombotic material at the CFV—these areas need to be stented to provide optimal inflow and outflow. **g,h**, Poststenting and venoplasty venogram; two Venovo stents (BD Medical), 160 × 120 mm proximally and 140 × 100 mm distally, were placed allowing brisk flow through the previously thrombosed iliofemoral segment. Notice the IVUS images confirming appropriate stent expansion.

reasonable, it could have been much higher if stented (as is in their concurrent stented population). Other factors such as the different population, intervening early enough to maximize thrombus removal, routine IVUS imaging, the team's high expertise, and use of direct oral anticoagulants may account for the lower stenting rate. The role of wall inflammation due to the acute

thrombus and to the procedure itself may also relate to a transient luminal stenosis that will later resolve. Further studies that replicate these results are however needed before such a practice of deferred stenting can be widely adapted.

As a final remark, given the lack of robust data, an individualized approach should be used when it comes to

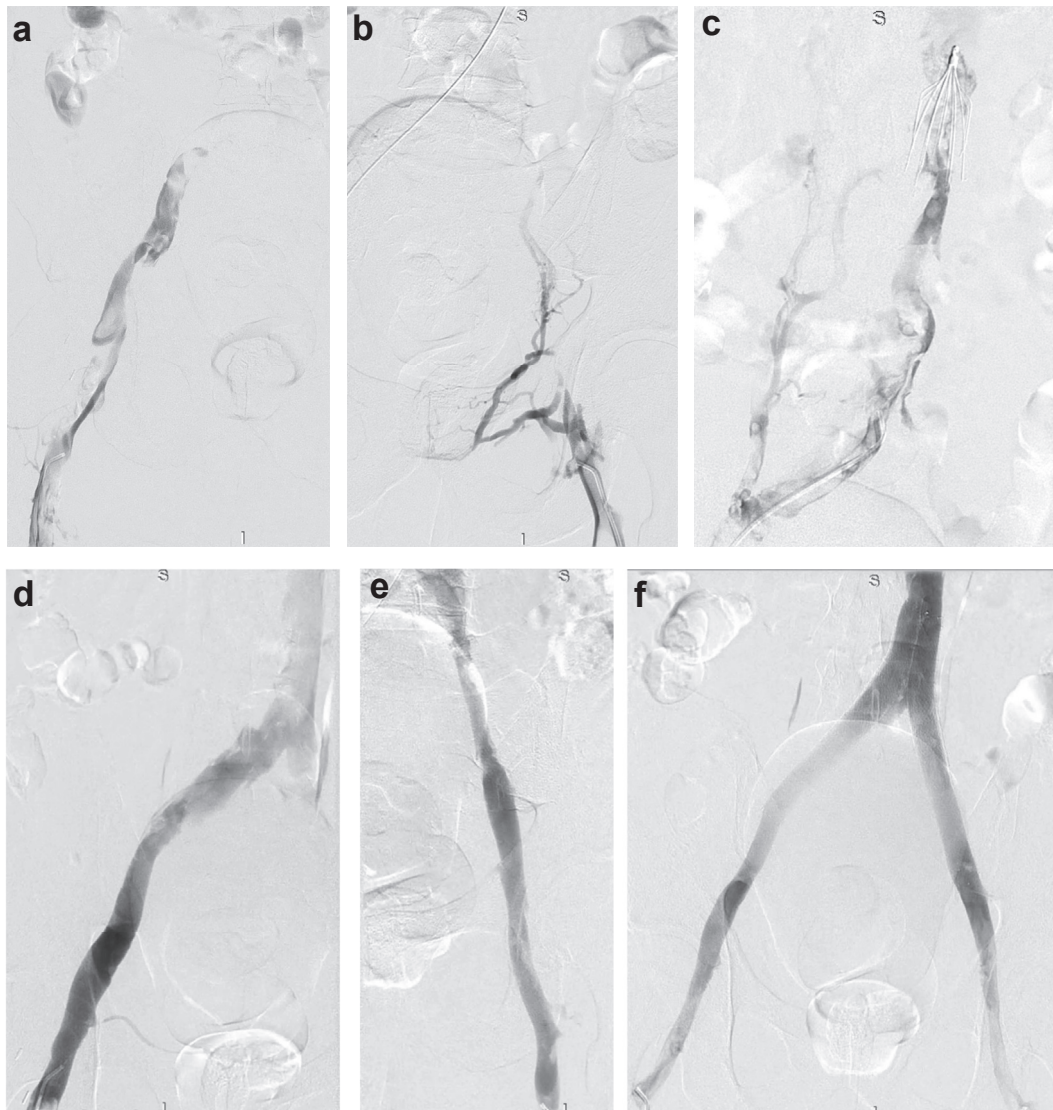


Fig 2. a-c, Extensive bilateral ilio-caval thrombosis extending to a caval filter at the level of the renal veins. d,e, Thrombus has been removed using the Indigo CAT 12 thrombectomy catheter (Penumbra); however, there is residual chronic material that could not be removed. f, Kissing stents VICI 14 × 100 were placed; thrombus can be seen throughout both iliac veins and in the inferior vena cava up to the filter. The diseased iliac segments were covered with 2 VICI stents (Boston Scientific Corporation) 140 × 120 mm. The final venogram confirmed brisk flow through both stents. The caval filter was also removed at the same session after completion of thrombus removal using the CAT 12 catheter through an internal jugular vein access.

stenting, both for stenting rates and for stenosis thresholds prompting stent placement. Providers should be urged to assess the clinical situation, vein/lesion characteristics, inflow, outflow, life expectancy, and preferences of individual patients, and consider stent placement when it seems more likely that benefits outweigh downsides and unknowns.

Stenting technique. After completion of thrombectomy, IVUS imaging is helpful to better assess an underlying compression, residual thrombus, and identification of the landing zones for optimal inflow and outflow. Compared with venography, IVUS imaging has been

shown to be superior for accurate lesion identification, and its use can potentially improve long-term patency.^{48,49} If IVUS imaging cannot be available, multiple venographic projections need to be obtained for better lesion identification.

IVUS imaging can be helpful in diameter measurement of an inflow healthy segment; however, after thrombectomy, a healthy segment is difficult to define;⁵⁰ veins can either be too dilated due to the acute thrombotic inflammation or to a chronic underlying prestenotic compression or spasm after an aggressive mechanical thrombectomy. Following the anatomic norms may be a better guide.⁵¹ Using the novel dedicated venous

stents, the common iliac vein should be typically stented with a 16 mm stent and the external iliac/common femoral vein with a 14/12 mm stent.⁵² Balloon predilatation one to one to the intended stent diameter is essential to “break” chronic webs of an underlying compression syndrome.

Despite lack of adequate evidence, it is the authors’ perspective that the length of the iliac stent should also be long enough (≥ 8 cm) to anchor at the external iliac segment. Such a strategy can protect from migration and prevent an acute angulated landing at the ilio-sacral curvature.⁵² Markers on the IVUS catheter shaft can be used for precise length measurements. It needs to be noted that long stenting lengths do not seem to be associated with lower patency rates.⁵³

Not infrequently, it may be necessary to stent from the ilio-caval confluence down to the common femoral vein (if there is residual disease/thrombus leading to $>50\%$ area or $>70\%$ diameter reduction) (Fig 1). Care should be taken to prevent jailing of the contralateral common iliac vein and jailing of the deep femoral vein when extending distally. Regarding the proximal landing zone, this can be better achieved with the novel dedicated venous stents that have uniform radial force and a high porosity. The best technique for a precise determination of the proximal landing zone is a combination of pull-back crossover venography (visualization of the entire confluence and the contralateral IVC wall) with IVUS imaging (visualization of the maximal point of compression). The traditional Wallstent (Boston Scientific Corporation), due to its weaker radial force at the edges, has to be extended into the IVC for 1 cm or more. Though not frequent, this has been recognized as a precipitating factor for contralateral iliac vein jailing and thrombosis.⁵⁴

When two stents are placed, short overlapping 2-3 cm is typically enough (longer overlap creates a rigid system prone to fracture and exposes more material burden to the endothelium). The overlapping segment should ideally be proximal to the superior ramus of the pubis where fractures usually occur.⁵⁵ The sequence of deployment (proximal to distal or distal to proximal) in this instance does not seem to matter.

Balloon postdilatation will allow good wall apposition of the stent, and a final IVUS run will confirm appropriate stent expansion. If not, additional aggressive ballooning will resolve residual stent compression.

Kissing stent configuration may be needed in instances of bilateral DVTs or when there is significant disease at the very proximal portion of the common iliac vein requiring deep extension into the IVC (Fig 2).

Surveillance and perioperative care. Appropriate compression should be applied at the end of the procedure before leaving the operating room/interventional suite (typically bandaging for the first few hours before transitioning to stockings). Anticoagulation should be

continued immediately postoperatively. The patient should be encouraged to walk as soon as hemostasis at the access site is considered safe, typically 3-6 hours postoperatively. Before discharge a duplex ultrasound imaging can identify early failures and need for reintervention. Patient should also have a defined anticoagulation plan consistent with the underlying DVT reason and the risk of recurrence, the complexity of the reconstruction (eg, stent extension into the common femoral vein), and current guidelines.^{4,56} For those who ended up with a stented iliofemoral segment, low-molecular-weight heparin for 2-6 weeks is preferred, due to its anti-inflammatory effects, before initiation of oral anticoagulants. An antiplatelet agent for 6 months or indefinitely depending on the patient’s risk profile can be considered. Appropriate referral to hematology is warranted in patients with an unprovoked DVT or possible thrombophilia. A follow-up office visit is suggested at 2-4 weeks, at 3, 6, and 12 months, and annually thereafter with duplex ultrasound imaging.⁵⁶⁻⁵⁸ Although there are no defined duplex criteria to trigger advanced imaging and reintervention, the combination of peak flow velocity (PFV) and analysis of the Doppler flow pattern at the stent inlet, along with in-stent velocity measurements (eg, ratio of in-stent to stent inlet PFV >3.5 or PFV in the stent >44 cm/s indicating $>50\%$ stenosis), can potentially diagnose a failing stent.^{57,59} Cross-sectional imaging can be occasionally needed in complex ilio-caval reconstructions and when stents have been extended below the inguinal ligament to evaluate their integrity and restenosis.

CONCLUSIONS

Stenting of the iliofemoral, compressed or diseased, segment noted to be present after thrombolysis or thrombectomy seems to be a critical component of a successful DVT intervention. The diameter of the stent, the length, and the landing zones, as well as appropriate anticoagulation and surveillance, are crucial determinants of a durable outcome.

AUTHOR CONTRIBUTIONS

Conception and design: EA, HJ

Analysis and interpretation: EA, SB, MR, HJ

Data collection: EA

Writing the article: EA, HJ

Critical revision of the article: EA, SB, MR, HJ

Final approval of the article: EA, SB, MR, HJ

Statistical analysis: Not applicable

Obtained funding: Not applicable

Overall responsibility: EA

DISCLOSURES

E.D.A. is on the speakers’ bureau and consults for BD Medical, Boston Scientific Corporation, Bentley, INARI Medical, Philips, Gore Medical, and ThinkSono; and has

received funding for research from ThinkSono. S.B. is on the speakers' bureau and consults for BD Medical, Boston Scientific Corporation, Medtronic, Gore Medical, Veyan, and Cook Medical; and has received funding for research from Veyan, Medtronic, and Boston Scientific Corporation. M.J.V.R. is on the speakers' bureau of Medtronic and INARI Medical. H.J. is on the speakers' bureau and consults for BD Medical, Boston Scientific Corporation, Bentley, and Optimed; and received funding for research from Medtronic, BD Medical, Boston Scientific Corporation, Bentley, Abbott Medical, Cook Medical, and Optimed.

REFERENCES

1. Heit JA. Epidemiology of venous thromboembolism. *Nat Rev Cardiol*. 2015;12:464–474.
2. Kahn SR, Shbaklo H, Lamping DL, et al. Determinants of health-related quality of life during the 2 years following deep vein thrombosis. *J Thromb Haemost*. 2008;6:1105–1112.
3. Broholm R, Sillesen H, Damsgaard MT, et al. Postthrombotic syndrome and quality of life in patients with iliofemoral venous thrombosis treated with catheter-directed thrombolysis. *J Vasc Surg*. 2011;54(6 Suppl):18S–25S.
4. Kakkos SK, Gohel M, Baekgaard N, et al. Editor's Choice - European society for vascular Surgery (ESVS) 2021 clinical practice guidelines on the management of venous thrombosis. *Eur J Vasc Endovasc Surg*. 2020;61:9–82.
5. Akesson H, Brudin L, Dahlstrom JA, Eklof B, Ohlin P, Plate G. Venous function assessed during a 5 year period after acute ilio-femoral venous thrombosis treated with anticoagulation. *Eur J Vasc Surg*. 1990;4:43e8.
6. Kahn SR, Shrier I, Julian JA, et al. Determinants and time course of the postthrombotic syndrome after acute deep venous thrombosis. *Ann Intern Med*. 2008;149:698e707.
7. Prandoni P, Ageno W, Ciammaichella M, et al. The risk of post-thrombotic syndrome (PTS) in patients with proximal deep vein thrombosis treated with the direct oral anticoagulants. *Intern Emerg Med*. 2020;15:447–452.
8. Johnson BF, Manzo RA, Bergelin RO, Strandness DE Jr. Relationship between changes in the deep venous system and the development of the postthrombotic syndrome after an acute episode of lower limb deep vein thrombosis: a one- to six-year follow-up. *J Vasc Surg*. 1995;21:307e12 [discussion: 13].
9. Delis KT, Bountouroglou D, Mansfield AO. Venous claudication in iliofemoral thrombosis: long-term effects on venous hemodynamics, clinical status, and quality of life. *Ann Surg*. 2004;239:118e26.
10. Comerota AJ, Kearon C, Gu CS, et al. Endovascular thrombus removal for acute iliofemoral deep vein thrombosis: analysis from a stratified multicenter randomised trial. *Circulation*. 2019;139:1162–1173.
11. Bashir R, Zack C, Zhao H, Comerota A, Bove A. Comparative outcomes of catheter-directed thrombolysis plus anticoagulation vs anticoagulation alone to treat lower-extremity proximal deep vein thrombosis. *JAMA Intern Med*. 2014;174:1494.
12. Haig Y, Enden T, Grøtta O, et al. Post-thrombotic syndrome after catheter-directed thrombolysis for deep vein thrombosis (CaVenT): 5-year follow-up results of an open-label, randomised controlled trial. *The Lancet Haematology*. 2016;3:e64–e71.
13. Notten P, Ten Cate-Hoek AJ, Arnoldussen CWKP, et al. Ultrasound-accelerated catheter-directed thrombolysis versus anticoagulation for the prevention of post-thrombotic syndrome (CAVA): a single-blind, multicenter, randomized trial. *Lancet Haematol*. 2020;7:e40–e49.
14. Jayed A, Machin M, Gwozdz AM, et al. Meta-analysis of lytic catheter-based intervention for acute proximal deep vein thrombosis in the reduction of post-thrombotic syndrome. *J Vasc Surg Venous Lymphat Disord*. 2023;11:866–875.
15. Thukral S, Salter A, Lancia S, Kahn SR, Vedantham S. Predictors of clinical outcomes of pharmacomechanical catheter-directed thrombolysis for acute iliofemoral deep vein thrombosis: analysis of a multicenter randomized trial. *J Vasc Interv Radiol*. 2022;33:1161–1170.
16. Go C, Chaer RA, Avgerinos ED. Catheter interventions for acute deep venous thrombosis: who, when and how. *Vasc Endovascular Rev*. 2020;5:e04.
17. Lichtenberg MKW, Stahlhoff S, Mlynczak K, et al. Endovascular mechanical thrombectomy versus thrombolysis in patients with iliofemoral deep vein thrombosis - a systematic review and meta-analysis. *Vasa*. 2021;50:59–67.
18. Harrison B, Hao F, Koney N, McWilliams J, Moriarty JM. Caval thrombus management: the data, where we are, and how it is done. *Tech Vasc Interv Radiol*. 2018;21:65–77.
19. Engelberger RP, Spirk D, Willenberg T, et al. Ultrasound-assisted versus conventional catheter-directed thrombolysis for acute iliofemoral deep vein thrombosis. *Circ Cardiovasc Interv*. 2015;8:e002027.
20. Ascher E, Chait J, Pavalonis A, Marks N, Hingorani A, Kibrik P. Fast-track thrombolysis protocol: a single-session approach for acute iliofemoral deep vein thrombosis. *J Vasc Surg Venous Lymphat Disord*. 2019;7:773–780.
21. Lichtenberg M, Stahlhoff WF, Özkapi A, de Graaf R, Breuckmann F. Safety, procedural success and outcome of the Aspirex S endovascular thrombectomy system in the treatment of iliofemoral deep vein thrombosis – data from the Arnsberg Aspirex registry. *Vasa*. 2019;48:341–346.
22. Robertson B, Neville E, Muck A, et al. Technical success and short-term results from mechanical thrombectomy for lower extremity iliofemoral deep vein thrombosis using a computer aided mechanical aspiration thrombectomy device. *J Vasc Surg Venous Lymphat Disord*. 2022;10:594–601.
23. Razavi C, Khalsa B, Openshaw L, Razavi MK. Single-session treatment of patients with symptomatic ilio-caval and iliofemoral deep vein thrombosis: technical results of a prospective pilot study. *J Vasc Interv Radiol*. 2022;33:183–188.
24. Dexter DJ, Kado H, Schor J, et al. Interim outcomes of mechanical thrombectomy for deep vein thrombosis from the All-comer CLOUT Registry. *J Vasc Surg Venous Lymphat Disord*. 2022;10:832–840.e2.
25. Aziz F, Comerota AJ. Quantity of residual thrombus after successful catheter-directed thrombolysis for iliofemoral deep venous thrombosis correlates with recurrence. *Eur J Vasc Endovasc Surg*. 2012;44:210–213.
26. Comerota AJ, Grewal N, Martinez JT, et al. Postthrombotic morbidity correlates with residual thrombus following catheter-directed thrombolysis for iliofemoral deep vein thrombosis. *J Vasc Surg*. 2012;55:768–773.
27. Avgerinos E, Saadeddin Z, Abou Ali AN, Pandya Y, Hager E, et al. Outcomes and predictors of failure of iliac vein stenting after catheter-directed thrombolysis for acute iliofemoral thrombosis. *J Vasc Surg Venous Lymphat Disord*. 2019;7:153–161.
28. Pouncey AL, Kahn T, Morris RI, Saha P, Thulasidasan N, Black SA. Risk factors and classification of reintervention following deep venous stenting for acute iliofemoral deep vein thrombosis. *J Vasc Surg Venous Lymphat Disord*. 2022;10:1051–1058.
29. Mewissen MW, Seabrook GR, Meissner MH, Cynamon J, Labropoulos N, Haughton SH. Catheter-directed thrombolysis for lower extremity deep venous thrombosis: report of a national multicenter registry. *Radiology*. 1999;211:39–49.
30. Foegh P, Jensen LP, Klitfod L, Broholm R, Baekgaard N. Factors associated with long-term outcome in 191 patients with ilio-femoral DVT treated with catheter-directed thrombolysis. *Eur J Vasc Endovasc Surg*. 2017;53:419e24.
31. Meissner MH, Gloviczki P, Comerota AJ, et al. Early thrombus removal strategies for acute deep venous thrombosis: clinical practice guidelines of the Society for Vascular Surgery and the American Venous Forum. *J Vasc Surg*. 2012;55:1449–1462.
32. Mahnken A, Thomson K, de Haan M, O'Sullivan G. CIRSE standards of practice guidelines on ilio-caval stenting. *Cardiovasc Intervent Radiol*. 2014;37:889–897.
33. Guni A, Machin M, Onida S, Shalhoub J, Davies AH. Acute iliofemoral DVT – what evidence is required to justify catheter-directed thrombolysis? *Phlebology*. 2021;36:339–341.
34. Carr S, Chan K, Rosenberg J, et al. Correlation of the diameter of the left common iliac vein with the risk of lower-extremity deep venous thrombosis. *J Vasc Intervent Radiol*. 2012;23:1467–1472.

35. Narayan A, Eng J, Carmi L, et al. Iliac vein compression as risk factor for left- versus right-sided deep venous thrombosis: case-control study. *Radiology*. 2012;265:949–957.
36. Raju S, Neglen P. High prevalence of nonthrombotic iliac vein lesions in chronic venous disease: a permissive role in pathogenicity. *J Vasc Surg*. 2006;44:136–143.
37. Gagne PJ, Gasparis A, Black S, et al. Analysis of threshold stenosis by multiplanar venogram and intravascular ultrasound examination for predicting clinical improvement after iliofemoral vein stenting in the VIDIO trial. *J Vasc Surg Venous Lymphat Disord*. 2018;6:48–56.
38. Stanley GA, Murphy EH, Plummer MM, Chung J, Modrall JG, Arko FR. Midterm results of percutaneous treatment for acute and chronic deep venous thrombosis. *J Vasc Surg*. 2011;54:1851.
39. Avgerinos ED, Hager ES, Naddaf A, Dillavou E, Singh M, Chaer RA. Outcomes and predictors of failure of thrombolysis for iliofemoral deep venous thrombosis. *J Vasc Surg Venous Lymphat Disord*. 2015;3:35–41.
40. Jayaraj A, Lucas M, Fuller R, Powell T, Kuykendall R. Improvement following restoration of inline flow argues against comprehensive thrombus removal strategies and for selective stenting in acute symptomatic iliofemoral venous thrombosis. *J Vasc Surg Venous Lymphat Disord*. 2023;11:119–126.
41. Vedantham S, Goldhaber SA, Julian JA, et al. Pharmacomechanical catheter-directed thrombolysis for deep-vein thrombosis. *N Engl J Med*. 2017;377:2240–2252.
42. Enden T, Haig Y, Klow NE, et al. Long-term outcome after additional catheter-directed thrombolysis versus standard treatment for acute iliofemoral deep vein thrombosis (the CaVenT study): a randomised controlled trial. *Lancet*. 2012;379:31–38.
43. Avgerinos ED, Chaer RA. The ATTRACTiveness of catheter directed thrombolysis. *J Vasc Surg Venous Lymphat Disord*. 2018;6:303.
44. O'Sullivan GJ, de Graaf R, Black SA. Just how attractive is the ATTRACT trial? *Cardiovasc Intervent Radiol*. 2018;41:1313–1317.
45. Murphy E, Gibson K, Sapoval M, Dexter DJ, Koluri R, et al. Pivotal study evaluating the safety and effectiveness of the abre venous self-expanding stent system in patients with symptomatic iliofemoral venous outflow obstruction. *Circ Cardiovasc Interv*. 2022;15:e010960.
46. Hofmann LR, Gagne P, Brown JA, Saunders A, Comerota A, VIVO Study Investigators. Twelve-month end point results from the evaluation of the Zilver Vena venous stent in the treatment of symptomatic iliofemoral venous outflow obstruction (VIVO clinical study). *J Vasc Surg Venous Lymphat Disord*. 2023;11:532–541.
47. Taha MA, Busuttill A, Bootun R, Davies AH. A systematic review on the use of deep venous stenting for acute venous thrombosis of the lower limb. *Phlebology*. 2019;34:115–127.
48. Gagne PJ, Tahara RW, Fastabend CP, et al. Venography versus intravascular ultrasound for diagnosing and treating iliofemoral vein obstruction. *J Vasc Surg Venous Lymphat Disord*. 2017;5:678–687.
49. Tran LM, Go C, Zaghoul M, et al. Intravascular ultrasound evaluation during iliofemoral venous stenting is associated with improved midterm patency outcomes. *J Vasc Surg Venous Lymphat Disord*. 2022;10:1294–1303.
50. Jayaraj A, Thaggard, Lucas M. Technique of stent sizing in patients with symptomatic chronic iliofemoral obstruction – the case for intravascular ultrasound-determined inflow channel stenting and associated long-term outcomes. *J Vasc Surg Venous Lymphat Disord*. 2023;11:634–641.
51. Raju S, Buck WJ, Crim W, Jayaraj A. Optimal sizing of iliac vein stents. *Phlebology*. 2018;33:451–457.
52. Sayed MH, Salem M, Desai KR, O'Sullivan GJ, Black SA. A review of the incidence, outcome, and management of venous stent migration. *J Vasc Surg Venous Lymphat Disord*. 2022;10:482–490.
53. Robertson B, Shapiro J, Muck A, et al. Venous stent patency is independent of total stented length in nonthrombotic iliac vein and post-thrombotic venous stenoses. *J Vasc Surg Venous Lymphat Disord*. 2023;11:339–345.
54. Murphy EH, Johns B, Varney E, Buck W, Jayaraj A, Raju S. Deep venous thrombosis associated with caval extension of iliac stents. *J Vasc Surg Venous Lymphat Disord*. 2017;5:8–17.
55. Cheng CP, Dua A, Suh GY, Shah RP, Black SA. The biomechanical impact of hip movement on iliofemoral venous anatomy and stenting for deep venous thrombosis. *J Vasc Surg Venous Lymphat Disord*. 2020;8:953–960.
56. Kearon C, Akl EA, Ornelas J, et al. Antithrombotic therapy for VTE disease CHEST guideline and expert Panel report. *Chest*. 2016;149:315–352.
57. Sebastian T, Barco S, Engelberger RP, et al. Duplex ultrasound investigation for the detection of obstructed ilio caval venous stents. *Eur J Vasc Endovasc Surg*. 2020;60:443–450.
58. Avgerinos ED, Labropoulos N. Duplex criteria for ilio caval stent obstruction: sounds of a cry for validated data. *Eur J Vasc Endovasc Surg*. 2020;60:451.

Submitted Sep 5, 2023; accepted Feb 13, 2024.